



^{131}I -mIBG Therapy in the Management of High-Risk Neuroblastoma: A Retrospective Study from a Tertiary Level Hospital in South India

A.R. Vishnu¹ Saumya Sunny¹ Julie Hephzibah¹ Leni G. Mathew² Rikki Rorima John²

¹Department of Nuclear Medicine, Christian Medical College, Vellore, Tamil Nadu, India

²Department of Paediatric Oncology, Christian Medical College, Vellore, Tamil Nadu, India

Address for correspondence Julie Hephzibah, MD, DNB, Department of Nuclear Medicine, Christian Medical College, Vellore 632004, Tamil Nadu, India (e-mail: drjulsan@cmcvellore.ac.in).

Ind J Med Paediatr Oncol 2025;46:71–76.

Abstract

Introduction Neuroblastoma is the most common extracranial solid tumor in childhood. The data on the treatment experience with ^{131}I iodine-meta-iodo-benzyl-guanidine (^{131}I -mIBG) and clinical outcome data are meager from India.

Objectives This article studies the efficacy and treatment outcomes in patients treated with ^{131}I -mIBG in high-risk neuroblastoma.

Materials and Methods The study group consisted of 201 consecutive patients (aged between 1 and 15 years) with biopsy-proven neuroblastoma who underwent ^{131}I -mIBG scans from 2012 to 2022. The majority of these children had a disease that was inoperable or had poor response to chemotherapy. Patients with positive scintigraphy were considered for therapy with ^{131}I -mIBG. The findings were analyzed and correlated with the final diagnosis and outcomes obtained from survival during follow-up and reviewing patient records.

Results Thirty-nine children, 22 males and 17 females, with a median age of 4 years had positive ^{131}I -mIBG scintigraphy. Intra-abdominal primary lesions and osseous lesions were the most common sites of uptake on ^{131}I -mIBG scan. Of these, 13 had upfront chemotherapy and 26 had surgery followed by chemotherapy. All the patients underwent therapy with ^{131}I -mIBG. Fourteen patients had multiple therapies while the remaining 25 had only one therapy. Eight patients had no follow-up, and 13 had disease relapse. The remaining 18 had regression of disease which was confirmed by follow-up ^{131}I -mIBG scintigraphy and with bone scintigraphy in patients with osseous metastases.

Conclusion ^{131}I -mIBG scintigraphy should be preferred in intermediate and high-risk neuroblastoma to know the extent of the disease and also for patient selection for early therapy with ^{131}I -mIBG. It holds significant utility in the management of metastatic neuroblastoma, facilitating palliative pain relief and tumor size reduction in inoperable or metastatic disease.

Keywords

- ▶ neuroblastoma
- ▶ ^{131}I -mIBG
- ▶ ^{131}I -mIBG therapy

Key Messages

High-risk neuroblastoma can be treated upfront with ¹³¹I-mIBG and used in advanced stages to improve overall survival.

Introduction

Neuroblastoma is the most common extracranial solid tumor of childhood which arises from neural crest cells that form the adrenal medulla and sympathetic ganglia.

About 50% of patients at diagnosis¹ present with metastasis most commonly to bone or marrow. Important prognostic factors are age at presentation, histological features, tumor ploidy, N-MYC gene amplification, and stage of the disease, which is based on the International Neuroblastoma Staging System (INSS).² The worst outcomes are noted in high-risk diseases defined as stage III or IV in children aged more than 18 months at diagnosis as well as those with N-MYC amplification.

The standard of care for high-risk neuroblastoma includes chemotherapy, surgery, myeloablative therapy, and radiation therapy followed by differentiation therapy using cis-retinoic acid. Despite this multimodality treatment, the outcome is poor³ with overall survival (OS) ranging from 10 to 60%. Immunotherapy using anti-GD2 antibodies has improved outcomes considerably in high-resource countries; however, this modality is currently prohibitively expensive and hence unavailable to the rest of the world. Iodine 131 meta-iodo-benzyl-guanidine (¹³¹I-mIBG) is one of the multimodality treatments that is used mainly in advanced stages of neuroblastoma.⁴ Treatment of these high-risk neuroblastoma is essential as this may help in planning the management of the disease.

The current study aimed to analyze the treatment outcomes and to look at the feasibility of this form of treatment as a future therapeutic option in this select group of patients from a tertiary care center in India.

Materials and Methods

Inclusion and Exclusion Criteria

Children aged 1 to 15 years, diagnosed to have high-risk neuroblastoma from 2012 to 2022 who had a positive ¹³¹I-mIBG scintigraphy were included in this study. Diagnosis of neuroblastoma was confirmed by a biopsy of either the primary tumor or bone marrow (BM) trephine and supported by elevated urine catecholamines. The disease was staged according to the revised INSS and the assessment of response was according to the International Neuroblastoma Response Criteria.² ¹³¹I-mIBG scintigraphy was done in 201 patients for metastatic workup, among which 168 patients had shown positive uptake. Thirty-nine patients among them who had a positive mIBG scintigraphy during the period of the study received treatment with ¹³¹I-mIBG for metastatic or inoperable disease or relapse of the disease after standard care based on decisions by the multidisciplinary tumor board that includ-

ed pediatric oncologists, surgeons, radiation oncologists, and nuclear medicine physicians.

¹³¹I-mIBG Imaging

¹³¹I-mIBG which was prepared in-house using carrier-free ¹³¹iodine was used⁵ to assess for mIBG uptake. A dose of 0.5 mCi was administered intravenously and whole-body planar images were acquired using a gamma camera (Infinia Hawkeye, GE Healthcare, Milwaukee, Wisconsin, United States) at 24, 48, and 72 hours postinjection. Anterior and posterior whole-body images were acquired with a window centered at 364 keV ± 15 and a matrix of 256 × 1024 for 450 s/step in three steps. Single-photon emission computed tomography (CT)/ low-dose CT was acquired for doubtful lesions and anatomical localization.⁶

Posttherapy ¹³¹I- mIBG whole-body scintigraphy in anterior and posterior projections was done on the third day after the therapy to look for any lesions not seen on the diagnostic pretherapy scans⁷ and also confirm the uptake of mIBG in the target lesions.

¹³¹I-mIBG Therapy

Patients were treated in a room specially designed for radioisotope therapy. ¹³¹I-mIBG was administered as slow infusion intravenously over 3 to 4 hours with hydration.

Thyroid gland blockade was provided with potassium perchlorate by oral administration from 2 days before therapy to 5 days posttherapy. Blood pressure and heart rate were monitored during the procedure and for 24 hours after treatment. There was no adverse reaction during or shortly after the administration of ¹³¹I-mIBG therapy for any of the patients. Dosage was given according to a weight-based regimen with a dose of 37 to 74 MBq/kg (1–2 mCi/kg) to all the patients and patients were discharged once the levels of exposure were < 50 micro-Sv at a 1-m distance which conferred to the Atomic Energy Regulatory Board, India standard guidelines.

Primary Outcome

Patients who were treated with ¹³¹I-mIBG were followed up after 6 months to look for response evaluation. ¹³¹I-mIBG scintigraphy and urinary catecholamine levels were done. Progression of the disease was considered when there was an increase in the intensity of ¹³¹I-mIBG uptake or any new lesions noted compared with the posttherapy scan and increase in urinary catecholamine levels (► Fig. 1). Partial regression of the disease was considered when there was a decrease in the number of lesions or intensity of lesions and decrease in the levels of urinary catecholamine (► Fig. 2).

Statistical Analysis

Categorical data were summarized using percentages. Numerical data were summarized as the means and standard deviations or medians and ranges. Due to the small sample size multivariable Cox regression for determining independent predictors of survival was not possible.

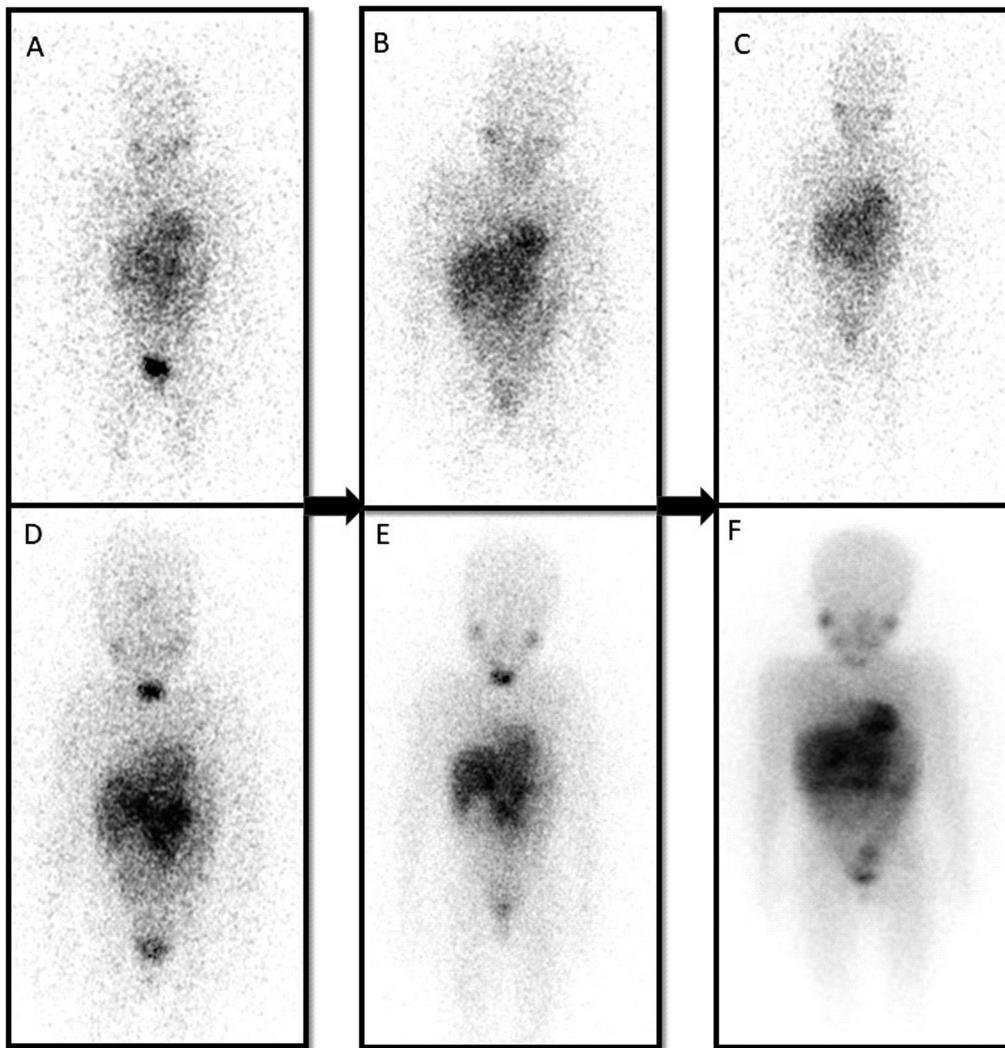


Fig. 1 A 6-year-old child with a primary lesion in the mediastinum (A). Progression of the disease as the areas of uptake have increased despite two ¹³¹iodine-meta-iodo-benzyl-guanidine (¹³¹I-mIBG) therapies on the posttherapy scans (B).

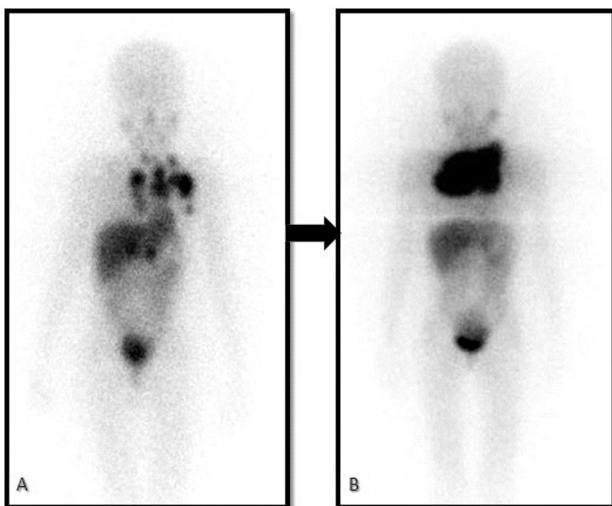


Fig. 2 A 7-year-old child with a primary abdomen lesion and multiple osseous metastases in the pretherapy scan (A-C). Partial regression is noted as the areas of uptake have significantly reduced after three ¹³¹iodine-meta-iodo-benzyl-guanidine (¹³¹I-mIBG) therapy as seen in the posttherapy images (D-F).

Ethical Approval Statement

The procedures followed were in accordance with the ethical standards of the responsible committee on human experimentation and with the Helsinki Declaration of 1964, as revised in 2013. Ethics Committee Approval was obtained from the Institutional Ethics Committee vide letter no. IRB Min No. 15495 (RETRO) dated June 28, 2023.

Results

Results

Thirty-nine of 201 children who had a positive ¹³¹I-mIBG scan received ¹³¹I-mIBG therapy. There were 22 boys and 17 girls with their ages ranging from 1 to 15 years with a median age of 4 years. Six children had stage III disease and all the rest had stage IV neuroblastoma. Twenty-four children received COJEC (cisplatin [C], vincristine [O], carboplatin [J], etoposide [E], and cyclophosphamide [C]) chemotherapy, 7 had carboplatin-etoposide/CADO (cyclophosphamide, doxorubicin, and vincristine), and the rest of the children who had chemotherapy elsewhere prior to coming to our hospital had

Table 1 Patient characteristics

Total no. of patients	39
Male	22
Female	17
Age at diagnosis	
Range	1–15
Mean	5.9
Median	4
Histopathology	
Neuroblastoma	35
Ganglioneuroblastoma	4
Immunohistochemistry	
Synaptophysin, chromogranin, and NSE	35 of 39 (4 were operated elsewhere)
Stage of the disease	
Stage 3	7
Stage 4	32
Presentation	
Inoperable primary	20
Skeletal metastasis	13
Primary with skeletal metastasis	3
Extraosseous metastasis	3
Treatments prior to ¹³¹ I-mIBG therapy	
Chemotherapy followed by	
Debulking surgery	28
Chemotherapy	11
¹³¹ I-mIBG therapies	57
1 dose	25
2 doses	10
3 doses	4
¹³¹ I-mIBG activity (mCi)	37–74 MBq/kg body weight 1–2 mCi/kg body weight
Follow-up	
Period	12–60 mo
Mean	25 mo
Results based on posttherapy ¹³¹ I-mIBG scan	
Regression	18
Progression	12
Lost to follow-up	9
Post ¹³¹ I-mIBG treatment in progressive disease	
Chemotherapy	7
Radiation therapy	1
Supportive/palliative treatment	4

Abbreviations: ¹³¹I-mIBG, ¹³¹iodine-meta-iodo-benzyl-guanidine; NSE, neuron-specific enolase.

OPEC (vincristine, prednisolone, etoposide, and chlorambucil)-based chemotherapy. The baseline characteristics of the cohort are shown in ► **Table 1**.

The location of the primary tumor was suprarenal in 10, retroperitoneal in 9, paraspinal in 4, thorax/neck in 4, and undetected primary with extensive bone and/or BM disease in 12 children. ¹³¹I-mIBG scan just prior to ¹³¹I-mIBG therapy showed uptake in multiple bones in 12 children, at primary site in 24 children, and 3 children with both primary and bone lesions. Indications for ¹³¹I-mIBG therapy included metastatic disease, refractory to standard therapy in 13, relapse/recurrence of disease in 9 (2 post-myeloablative therapy relapse), and inoperable primary with or without metastasis in 17. ¹³¹I-mIBG therapy was given with a curative intent for 6 children and in the remaining 33 it was given with palliative intent. Twenty-five patients had received a single dose of ¹³¹I-mIBG therapy.

For patients who had positive ¹³¹I-mIBG scintigraphy in the follow-up scan done 6 months after the first therapy underwent further doses of ¹³¹I-mIBG therapy, two doses were given for 10 patients and three doses for 4 patients.

Eighteen patients (46%) had partial regression of the disease identified by follow-up ¹³¹I-mIBG scintigraphy and catecholamine levels, 12 patients (30%) had progression of the disease, and 9 patients had been lost to follow-up. The median follow-up was 21 months (range: 10–60 months). They were also regularly followed up with complete blood count profile to look for any thrombocytopenia and neutropenia which are the most common side effects of ¹³¹I-mIBG therapy. Among the 30 children who were followed up, 18 patients had a regression and were doing well on the last follow-up. Among the 12 patients who had progression of the disease, irinotecan and isotretinoin acid-based chemotherapy and radiation therapy were given to 7 children and the remaining 5 children succumbed to the disease during the follow-up.

Discussion

High-risk neuroblastoma is most often associated with poor OS and mostly presents with metastases at initial presentation.¹ Current imaging guidelines for staging neuroblastoma are based on the INSS which recommends CT/magnetic resonance imaging for primary disease and ¹³¹I-mIBG for metastatic disease.

Although ¹²³I-mIBG is recommended, due to unavailability in the Indian setting, ¹³¹I-mIBG is used for pretherapy workup and subsequent therapy. Our study included 201 patients diagnosed with neuroblastoma who underwent ¹³¹I-mIBG scintigraphy as it is useful for documentation of primary and metastatic lesions and also to assess response to therapy, whereas 18F-fluorodeoxyglucose positron emission tomography (PET)/CT has only a complementary role for response assessment.⁸ Among them 39 patients with positive ¹³¹I-mIBG scintigraphy were referred for therapy with ¹³¹I-mIBG.

Long-term survival of children with inoperable or disseminated neuroblastoma diagnosed after 1 year of age remains largely unsatisfactory. This may be attributed to the fact that

current treatment commonly fails to completely eradicate the disease. It is also noted that 70% of remission rates are achieved by surgical resection, chemotherapeutic agents, and radiation therapy. Despite these treatments, there are high chances of relapse rate,⁹ possibly due to the aggressive nature of the disease.

Approximately 75% of neuroblastomas have ¹³¹I-mIBG uptake¹⁰ which makes it an effective therapeutic agent and can be used for treatment upfront as in our study. ¹³¹I-mIBG has proven to be useful for inoperable tumors, to improve overall disease-free survival rates, and reduce bone pain. Irrespective of some success, ¹³¹I-mIBG systemic therapy is still not the mainstay of treatment. ¹³¹I-mIBG therapy dosage used in neuroblastoma varies among different centers and is used in low and high doses. In our study, we had used doses ranging from 1 to 2 mCi/kg which can be used to achieve a response in the form of palliative pain reduction. This low dose does not require the use of a subsequent stem cell transplantation as it is associated with lower hematological toxicity compared with a high-dose regimen. ¹³¹I-mIBG were given at a high dose ranging from 12 to 20 mCi/kg body weight,¹¹ which are mainly administered as a myeloablative dose before stem cell transplantation without many complications as seen in various studies.

Most of the patients in our study had upfront treatment with either chemotherapy (26/39, 66%) or surgery (11/39, 28%), except for two patients who presented with an inoperable primary and were given upfront ¹³¹I-mIBG as induction therapy.¹² All of the patients presented with advanced-stage disease with bone and BM metastasis corresponding to high-risk neuroblastoma.¹ Various studies suggested a time interval of 2 to 6 months between treatment sessions and in our study, the interval was 6 months.¹³ Though various objective response scales like the Curie scale¹⁴ are available to look for treatment response, it was not used in our study partly as it was a retrospective study and few were lost to follow-up.

Only a few minor side effects were observed during the ¹³¹I-mIBG infusion and 3 to 4 days posttherapy, some patients complained of temporary nausea and vomiting.

Various studies have demonstrated that these side effects can be managed symptomatically with antiemetics.¹⁵ No serious acute side effects, such as hypertensive encephalopathy, accelerated hypertension, or death, were seen during therapy. Change in thyroid function was not observed in the follow-up patients as there was an adequate pretherapy blockade of the thyroid with perchlorate, although there is long-term thyroid complication reported in patients treated with ¹³¹I-mIBG.¹⁶

Patients who were lost to follow-up were mainly due to bleak prognosis and the moribund state as there was a lack of effective salvage treatment.¹⁷

We have outlined our experience in a tertiary care hospital in South India in treating high-risk neuroblastoma with ¹³¹I-mIBG therapy. Among those treated, 18 (46%) patients were found to have partial regression of the disease which is in comparison to other studies,¹⁸ though cannot be an independent predictor of OS.¹¹ Johnson et al also demonstrated similar outcomes which favored the use of ¹³¹I-mIBG

therapy in the standard-of-care treatment of high-risk neuroblastoma with multiple and subsequent doses.¹⁹

Future Directions

This study and other contemporary studies indicate that ¹³¹I-mIBG therapy can achieve a significant reduction in disease burden and pain in high-risk neuroblastoma patients. With the development of new radiotracers in the form of fluorinated form of mIBG, 18F-meta-fluorobenzylguanidine to detect lesions using PET²⁰ with improved lesion detection, the utility of ¹³¹I-mIBG therapy is going to become included in the management of neuroblastoma.

Limitations

Our study had limitations which included the retrospective nature of the study from a single institution and the small sample size. In addition, a standardized protocol for dosimetry of the ¹³¹I-mIBG therapy is not available.

Conclusion

¹³¹I-mIBG scintigraphy serves as a crucial tool for disease staging and patient stratification for ¹³¹I-mIBG therapy. It holds significant utility in the management of metastatic neuroblastoma, facilitating tumor size reduction, particularly in cases where surgical interventions or initial chemotherapy and radiation treatments have proven ineffective.

Note

The manuscript has been read and approved by all the authors, that the requirements for authorship have been met, and each author believes that the manuscript represents honest work.

Patient Consent

Waiver of consent form obtained as it's a retrospective study.

Conflict of Interest

None declared.

References

- DuBois SG, Kalika Y, Lukens JN, et al. Metastatic sites in stage IV and IVS neuroblastoma correlate with age, tumor biology, and survival. *J Pediatr Hematol Oncol* 1999;21(03):181-189
- Orr KE, McHugh K. The new International Neuroblastoma Response Criteria. *Pediatr Radiol* 2019;49(11):1433-1440
- Yu AL, Gilman AL, Ozkaynak MF, et al; Children's Oncology Group. Anti-GD2 antibody with GM-CSF, interleukin-2, and isotretinoin for neuroblastoma. *N Engl J Med* 2010;363(14):1324-1334
- Garaventa A, Bellagamba O, Lo Piccolo MS, et al. ¹³¹I-metaiodobenzylguanidine (¹³¹I-MIBG) therapy for residual neuroblastoma: a mono-institutional experience with 43 patients. *Br J Cancer* 1999;81(08):1378-1384
- Oommen R, Shanthly N, Subramani N, et al. In-house preparation of iodine -131 metaiodo benzyl guanidine for scintigraphy of neuroendocrine tumors. Fourteen years experience in South India. *Hell J Nucl Med* 2007;10(03):164-166
- Verma P, Chanadana, Hephzibah J, Shanthly N, Oommen R. Iodine-131 MIBG SPECT/CT in neuroendocrine tumours: an institutional experience. *Indian J Nucl Med* 2012;27(04):246-248
- Wakabayashi H, Kayano D, Inaki A, et al. Diagnostic use of post-therapy ¹³¹I-meta-iodobenzylguanidine scintigraphy in consolidation therapy for children with high-risk neuroblastoma. *Diagnosics (Basel)* 2020;10(09):663
- Taggart DR, Han MM, Quach A, et al. Comparison of iodine-123 metaiodobenzylguanidine (MIBG) scan and [¹⁸F]fluorodeoxyglucose positron emission tomography to evaluate response after iodine-131 MIBG therapy for relapsed neuroblastoma. *J Clin Oncol* 2009;27(32):5343-5349
- Bansal D, Marwaha RK, Trehan A, Rao KLN, Gupta V. Profile and outcome of neuroblastoma with conventional chemotherapy in children older than one year: a 15-years experience. *Indian Pediatr* 2008;45(02):135-139
- DuBois SG, Mody R, Naranjo A, et al. MIBG avidity correlates with clinical features, tumor biology, and outcomes in neuroblastoma: a report from the Children's Oncology Group. *Pediatr Blood Cancer* 2017;64(11):10
- Schmidt M, Simon T, Hero B, et al. Is there a benefit of ¹³¹I-MIBG therapy in the treatment of children with stage 4 neuroblastoma? A retrospective evaluation of The German Neuroblastoma Trial NB97 and implications for The German Neuroblastoma Trial NB2004. *Nucl Med (Stuttg)* 2006;45(04):145-151, quiz N39-N40
- Hoefnagel CA, De Kraker J, Valdés Olmos RA, Vouïte PA. ¹³¹I-MIBG as a first-line treatment in high-risk neuroblastoma patients. *Nucl Med Commun* 1994;15(09):712-717
- Howard JP, Maris JM, Kersun LS, et al. Tumor response and toxicity with multiple infusions of high dose ¹³¹I-MIBG for refractory neuroblastoma. *Pediatr Blood Cancer* 2005;44(03):232-239
- Anongpornjossakul Y, Sriwatcharin W, Thamnirat K, et al. Iodine-131 metaiodobenzylguanidine (¹³¹I-mIBG) treatment in relapsed/refractory neuroblastoma. *Nucl Med Commun* 2020;41(04):336-343
- Sisson JC, Shapiro B, Hutchinson RJ, et al. Predictors of toxicity in treating patients with neuroblastoma by radiolabeled metaiodobenzylguanidine. *Eur J Nucl Med* 1994;21(01):46-52
- Clement SC, van Rijn RR, van Eck-Smit BLF, et al. Long-term efficacy of current thyroid prophylaxis and future perspectives on thyroid protection during ¹³¹I-metaiodobenzylguanidine treatment in children with neuroblastoma. *Eur J Nucl Med Mol Imaging* 2015;42(05):706-715
- Radhakrishnan V, Raja A, Dhanushkodi M, Ganesan TS, Selvaluxmy G, Sagar TG. Real world experience of treating neuroblastoma: experience from a tertiary cancer centre in India. *Indian J Pediatr* 2019;86(05):417-426
- de Kraker J, Hoefnagel KA, Verschuur AC, van Eck B, van Santen HM, Caron HN. Iodine-131-metaiodobenzylguanidine as initial induction therapy in stage 4 neuroblastoma patients over 1 year of age. *Eur J Cancer* 2008;44(04):551-556
- Johnson K, McGlynn B, Saggio J, et al. Safety and efficacy of tandem ¹³¹I-metaiodobenzylguanidine infusions in relapsed/refractory neuroblastoma. *Pediatr Blood Cancer* 2011;57(07):1124-1129
- Samim A, Blom T, Poot AJ, et al. [¹⁸F]mFBG PET-CT for detection and localisation of neuroblastoma: a prospective pilot study. *Eur J Nucl Med Mol Imaging* 2023;50(04):1146-1157