



# Pediatric Scapular Cavernous Hemangioma Presenting with Kasabach–Merritt Syndrome and Controlled by Preoperative Angioembolization: A Case Report

Pooja Pande<sup>1</sup>  Suraj Bhamé<sup>1</sup> Harshit Bansal<sup>1</sup> Raghvesh Ranjan<sup>2</sup> Soumitra Saha<sup>3</sup>

<sup>1</sup>Department of Radiodiagnosis, Homi Bhabha Cancer Hospital, Tata Memorial Center, Varanasi, Uttar Pradesh, India

<sup>2</sup>Division of Pediatric Oncology, Department of Medical Oncology, Homi Bhabha Cancer Hospital, Tata Memorial Center, Varanasi, Uttar Pradesh, India

<sup>3</sup>Division of Paediatric Surgical Oncology, Department of Surgical Oncology, Homi Bhabha Cancer Hospital, Tata Memorial Center, Varanasi, Uttar Pradesh, India

**Address for correspondence** Pooja Pande, MD, Department of Radiodiagnosis, Homi Bhabha Cancer Hospital, Tata Memorial Center, Varanasi, Uttar Pradesh, India (e-mail: puja.pande@gmail.com).

Ind J Med Paediatr Oncol

## Abstract

Intraosseous hemangioma is a common and benign vascular tumor with a propensity to occur in any bone of the body. Although the most common skeletal sites are the craniofacial bones and the spine, hemangioma of the scapula is a rare occurrence, which is rarer in the pediatric population. Kasabach–Merritt syndrome (KMS) is characterized by the combination of a rapidly growing vascular tumor, thrombocytopenia, microangiopathic hemolytic anemia, and consumptive coagulopathy. This condition can cause massive bleeding even after minor trauma and immediate operative management is usually contraindicated.

We report a rare case of KMS in an 8-year-old girl with cavernous hemangioma of the scapula presenting with progressively increasing shoulder mass, thrombocytopenia, and serially falling hemoglobin levels. She was treated with preoperative angioembolization to manage the consumptive coagulopathy followed by surgery poststabilization. Intraosseous hemangiomas, while benign, can show aggressive features on imaging and angioembolization can be a life-saving tool in the management of vascular tumors presenting with consumptive coagulopathy. Intraosseous hemangiomas, while benign, can show aggressive features on imaging and angioembolization can be a life-saving tool in the management of vascular tumors presenting with consumptive coagulopathy.

## Keywords

- ▶ hemangioma
- ▶ pediatric
- ▶ scapula
- ▶ angioembolization
- ▶ Kasabach–Merritt
- ▶ intraosseous

## Introduction

Intraosseous hemangiomas are rare benign tumors that arise from the intrinsic vasculature of the bone, which account for 1% of all primary skeletal neoplasms. About 75% of these tumors occur in the vertebral body followed by craniofacial bones and 15 to 20% of the tumors occur in the scapula, ribs,

clavicle, and pelvic bones.<sup>1,2</sup> These tumors are most commonly seen in the fifth decade of life but can occur at any age with a slightly high prevalence in females (male:female = 1:1.5).<sup>3</sup> Some authors deem these lesions to be regarded as hamartomas; hence, have not been included in the 2018 International Society for the Study of Vascular Anomalies (ISSVA) classification of vascular anomalies.<sup>4</sup> However,

DOI <https://doi.org/10.1055/s-0044-1790520>.  
ISSN 0971-5851.

© 2024. The Author(s).

This is an open access article published by Thieme under the terms of the Creative Commons Attribution License, permitting unrestricted use, distribution, and reproduction so long as the original work is properly cited. (<https://creativecommons.org/licenses/by/4.0/>)

Thieme Medical and Scientific Publishers Pvt. Ltd., A-12, 2nd Floor, Sector 2, Noida-201301 UP, India

cavernous hemangioma is classified as a venous malformation in the slow-flow lesion category by the ISSVA.<sup>5</sup>

The most common primary benign neoplasm of the scapula is osteochondroma and the occurrence of an intraosseous hemangioma in the scapula is exceedingly rare, erstwhile only two reported cases in the literature to the best of our knowledge.<sup>6</sup>

Kasabach–Merritt syndrome (KMS) is a rare and life-threatening thrombocytopenic coagulopathy associated with vascular tumors, specific to tumors such as kaposiform hemangioendothelioma and tufted angioma.<sup>7</sup>

We present a rare case of a large cavernous hemangioma of the scapula in pediatric age group presenting with severe thrombocytopenia and anemia as per KMS. The condition was managed by preoperative angioembolization following which a total scapulectomy was performed after achieving hemodynamic stabilization.

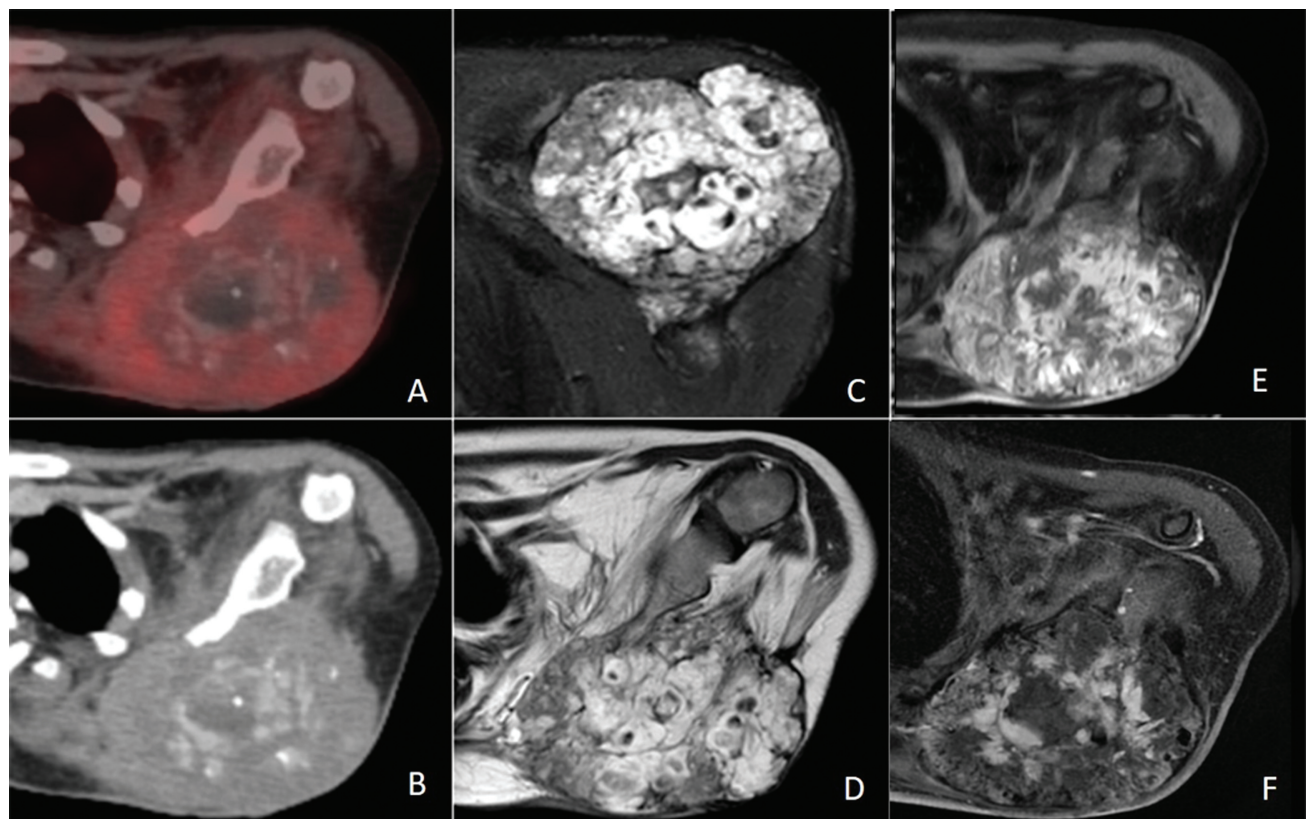
## Case Report

An 8-year-old female child was referred to a tertiary cancer center with chief complaints of swelling in the left shoulder region since 1 year and a less than 1-month old history of recent rapid increase in size. On local examination, the swelling was tender, associated with decreased abduction and external rotation movements of the shoulder joint, and

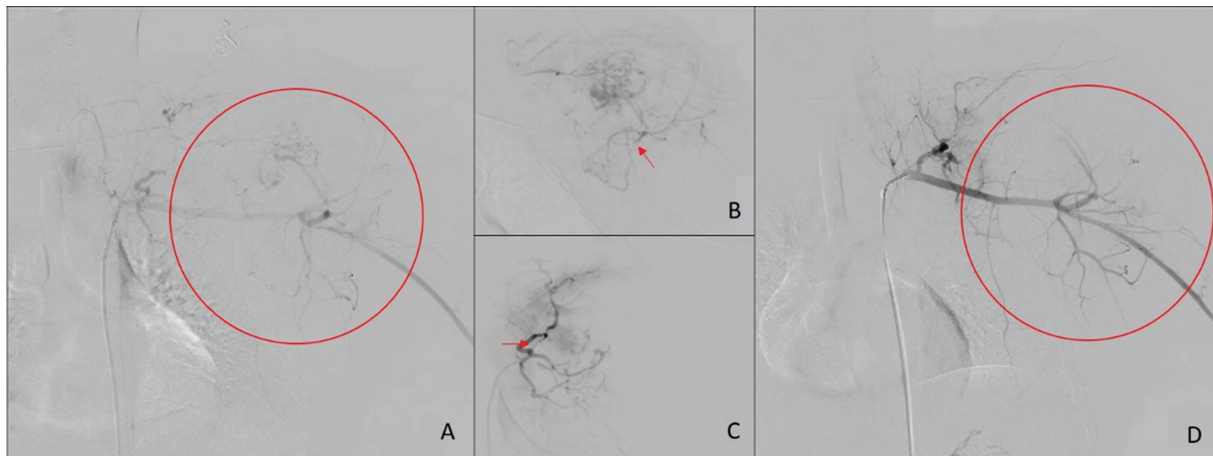
with bluish discoloration of the overlying skin. Routine blood investigations revealed thrombocytopenia with platelet count of  $18 \times 10^9/L$  and a baseline hemoglobin level of 10.7 g/dL. Baseline hematocrit level was 32.6%, mean corpuscular volume was 69.2 fL, mean corpuscular hemoglobin (MCH) was 22.6 pg, MCH concentration 32.7 g/dL, and red cell distribution width was 15.1%CV. A normal international normalized ratio value of 1.2 and prothrombin time of 14.3 with elevated activated partial thromboplastin time (aPTT) level of 34.6 were observed. The white blood cell count was normal with raised value of eosinophils (15%). Giant platelets were seen on a peripheral blood smear. Immature platelet fraction test was not performed.

Radiograph revealed an expansile lytic soft tissue mass arising from the left scapula causing destruction of the blade without any matrix within. Contrast-enhanced computed tomography (CECT) imaging was performed before referral and revealed an aggressive bone tumor of the left scapula showing a heterogeneously enhancing soft tissue component. The lesion was arising from the bone rather than secondary involvement of the bone by extraosseous soft tissue, ruling out rhabdomyosarcoma. The lack of sclerotic or cartilaginous matrix favored a possibility of Ewing's sarcoma over osteogenic sarcoma or a malignant cartilaginous tumor.

Baseline fluorine-2-fluoro-2-deoxy-d-glucose (<sup>18</sup>F-FDG) positron emission tomography (PET) CECT scan was



**Fig. 1** Axial positron emission tomography (PET) contrast-enhanced computed tomography (CECT) (A) and CECT (B) section showing fluorine-2-fluoro-2-deoxy-d-glucose (FDG) avid soft tissue mass with central pooling of contrast and calcific foci arising from the left scapula. Coronal short-tau inversion recovery (STIR) (C) and T2 axial (D) section showing predominantly hyperintense mass involving the left scapula with hypointense calcific foci. Axial T1 fat-saturated postcontrast preembolization status (E) and postembolization status (F) section showing significant decrease in the intense enhancement seen within the soft tissue mass postembolization procedure.



**Fig. 2** Digital subtraction angiography (DSA) angiography from left subclavian artery (A) showing parenchymal blush. Selective cannulation of arterial feeders (B), (C) arising from the left subclavian artery. Postembolization DSA from left subclavian artery (D) showing no parenchymal blush.

performed for staging the tumor after a primary suspicion of an aggressive malignant bone tumor like Ewing's sarcoma on the basis of imaging review. PET showed an expansile lytic soft tissue mass arising from the scapula showing central pooling of contrast and multiple tiny foci of calcifications within, likely phleboliths (►Fig. 1A, B). FDG uptake was seen peripherally in the soft tissue. No other area of abnormal tracer uptake was noted. For better mass characterization, a gadolinium-enhanced magnetic resonance imaging (MRI) was performed (►Fig. 1C–E). MRI revealed a large soft tissue mass arising from the blade of the left scapula which was predominantly hyperintense on T2-weighted imaging, measuring  $9.4 \times 8.6 \times 9.7$  cm.

The mass showed extraosseous extension with displacement and atrophy of the left deltoid and infraspinatus muscles and progressive filling of contrast on dynamic postcontrast imaging. The mass showed characteristics of hemangioma on imaging. Due to the aggressive type of destruction of the bone, size, location of tumor, and age profile, biopsy of the mass was planned to rule out any evidence of malignancy.

Repeat hemogram performed after 24 hours revealed fall in hemoglobin levels from the baseline level of 10.7 to 8.7 g/dL within 24 hours with persistent thrombocytopenia and elevated aPTT. The child was admitted for platelet and hemoglobin correction before performing an ultrasound-guided biopsy of the mass. Histopathology report revealed a tumor composed of variably sized, dilated, thin- and thick-walled vessels lined by a single layer of flat endothelial cells with focal areas showing hemosiderin-laden macrophages, hyalinization, and necrosis. No evidence of atypia/malignancy was found. After immunohistochemistry, CD34 highlighted endothelial cells while TTF-1, CD99, and NKX 2.2 were negative, which ruled out malignancy. After the diagnosis of cavernous hemangioma was confirmed, left scapulectomy was planned for the child. However, due to the ongoing consumptive coagulopathy, preoperative embolization of the tumor was performed.

Digital subtraction angiography was performed (►Fig. 2) which showed a predominant supply to the tumor by arterial feeders arising from the thyrocervical branch of subclavian

artery and subscapular branch of the axillary artery. These feeders were selectively embolized by 250- to 350- $\mu$ m sized polyvinyl alcohol particles and gelfoam. Considerable reduction in tumor blush was observed postembolization. Stabilization of platelets and hemoglobin values with normal aPTT was achieved postembolization. A repeat MRI confirmed decrease in vascularity within the tumor (►Fig. 1F) after which the child underwent scapulectomy. Final specimen histopathology report reconfirmed diagnosis of cavernous hemangioma with no features of atypia. The child underwent follow-up X-ray examination after 8 weeks of surgery, which revealed improvement in symptoms and no evidence of recurrence. The child was put on a 3-monthly follow-up regimen. Follow-up after 6 months of surgery revealed no fresh complaints, healthy surgical wound, and the child undergoing physiotherapy for shoulder, elbow, and fingers' range of motion exercises.

## Discussion

Scapular intraosseous hemangioma is a rare benign vascular tumor. Primary intraosseous hemangiomas are benign vascular tumors of small and large caliber vascular channels that are intrinsic to the bone of origin.<sup>3</sup> There are four primary types of intraosseous hemangiomas<sup>8</sup>: capillary, cavernous, venous, and arteriovenous. Most of the reported skeletal cavernous hemangiomas in the scientific literature have been published as single clinical case format, with nearly all lesions occurring in the craniofacial skeleton. This is the first reported case of a cavernous hemangioma occurring in the scapula to the best of our knowledge. Cavernous intraosseous hemangiomas account for about 0.2% of all tumors and 10% of benign tumors of the skull.<sup>9</sup> Cavernous hemangiomas of the skull usually have a size ranging from 15 to 25 mm at the time of clinical presentation.<sup>9</sup> Lesions as large as 8 cm in diameter at the time of diagnosis have also been described.<sup>9</sup> The natural history of this lesion has not yet been well understood. Osseous cavernous hemangiomas are known to grow progressively and spontaneous involution is rare. Thus, surgical intervention is recommended in the setting

of progressive pain and cosmetic reasons, but rarely for avoidance of complications like neurovascular bundle damage and hemorrhage depending on the location of the lesion.<sup>10</sup>

An association of bone marrow involvement causing cytopenia through the progression of clonal hematopoiesis is well understood with myeloid malignancies such as myelodysplastic syndromes or acute myeloid leukemia.<sup>11</sup> Secondary metastatic involvement to the bones in various types of cancers can lead to bone marrow failure syndromes causing cytopenia, resulting from the various proinflammatory cellular responses across carcinogenesis pathways.<sup>12</sup> In Maffucci syndrome, characterized by multiple enchondromas in bones, skeletal deformities, and cutaneous hemangiomas, an association with thrombocytopenia is secondary to the platelet-trapping process within the cutaneous lesions. However, the differential diagnosis for an isolated bone tumor with thrombocytopenia are limited to highly vascular lesions like intraosseous cavernous hemangioma, capillary hemangioma, venous hemangioma, and arteriovenous malformation.<sup>13</sup> In such cases, endothelial or vessel wall abnormalities and an abnormal blood flow cause turbulence or increased stasis which secondarily increases the clotting tendency.<sup>13</sup> Stasis and trapping of blood within vascular tumors can cause platelet activation and fibrinogen consumption.<sup>14</sup> After the first published report in 1940 by Kasabach and Merritt on growing skin hemangioma with thrombocytopenic purpura in a newborn baby, this association of hemangioma with thrombocytopenia and consumptive coagulopathy has been known as KMS.<sup>15</sup>

This syndrome can have a high mortality rate between 12 and 50%. Death results from severe hemorrhage related to disseminated intravascular coagulation, local invasion of vital structures, high output cardiac failure, multiorgan failure, or sepsis.<sup>15</sup> Most of the reported syndromes were associated with cutaneous hemangiomas as well as tumors present anywhere in the body with retroperitoneal tumors having a high mortality rate of approximately 60%.<sup>16</sup>

Surgery is the definitive treatment. However, surgery can be contraindicated in the setting of this syndrome due to the increased propensity of massive uncontrollable tumoral hemorrhage even with minor trauma. Therefore, it is vital to stabilize the hemodynamic and clotting parameters prior to planning a surgical intervention. While the treatment is largely supportive, reports of successful management of the syndrome are available with radiation therapy, aminocaproic acid, and corticosteroids.<sup>7</sup> Platelet transfusion is not recommended except in the case of active bleeding as the transfused platelets can get trapped in the tumor and lead to further abnormal coagulation and worsening of KMS.<sup>17</sup> Transarterial embolization is a widely accepted procedure to minimize perioperative hemorrhage and facilitate resection of vascular tumors and is commonly practiced for vertebral hemangiomas.<sup>18</sup> We report the first such case of utilization of transarterial embolization in a child with scapular hemangioma to manage the KMS and achieve hemostasis before undergoing definitive scapulectomy. After a thorough literature

search, this is also the first reported case of a scapular cavernous hemangioma in a pediatric patient.

#### Declaration of the Patient Consent Form

Declared and attached.

#### Conflict of Interest

None declared.

#### Acknowledgment

None.

#### References

- 1 Chandra SP, Singh P, Kumar R, et al. Long-term outcome of treatment of vertebral body hemangiomas with direct ethanol injection and short-segment stabilization. *Spine J* 2019;19(01): 131–143
- 2 Kaleem Z, Kyriakos M, Totty WG. Solitary skeletal hemangioma of the extremities. *Skeletal Radiol* 2000;29(09):502–513
- 3 Wenger DE, Wold LE. Benign vascular lesions of bone: radiologic and pathologic features. *Skeletal Radiol* 2000;29(02):63–74
- 4 George A, Mani V, Noufal A. Update on the classification of hemangioma. *J Oral Maxillofac Pathol* 2014;18(4, Suppl 1): S117–S120
- 5 Legiehn GM, Heran MKS. Venous malformations: classification, development, diagnosis, and interventional radiologic management. *Radiol Clin North Am* 2008;46(03):545–597, vi
- 6 Altwaijri NA, Fakeeha J, Alshugair I. Osteochondroma of the scapula: a case report and literature review. *Cureus* 2022;14(10):e30558
- 7 Mahajan P, Margolin J, Iacobas I. Kasabach-Merritt phenomenon: classic presentation and management options. *Clin Med Insights Blood Disord* 2017;10:1179545X17699849
- 8 Heckl S, Aschoff A, Kunze S. Cavernomas of the skull: review of the literature 1975–2000. *Neurosurg Rev* 2002;25(1-2):56–62, discussion 66–67
- 9 Rumana M, Khursheed N, Farhat M, Othman S, Masood L. Congenital intraosseous cavernous hemangioma of the skull: an unusual case. *Pediatr Neurosurg* 2013;49(04):229–231
- 10 Sáenz AA, Porto NF, Sánchez MP. Intraosseous cavernous hemangioma: presentation of a clinical case. *Egypt J Neurosurg* 2018;33(01):22
- 11 Trowbridge JJ, Starczynowski DT. Innate immune pathways and inflammation in hematopoietic aging, clonal hematopoiesis, and MDS. *J Exp Med* 2021;218(07):e20201544
- 12 Gaspar BL, Sharma P, Das R. Anemia in malignancies: pathogenetic and diagnostic considerations. *Hematology* 2015;20(01): 18–25
- 13 Rodriguez V, Lee A, Witman PM, Anderson PA. Kasabach-Merritt phenomenon: case series and retrospective review of the mayo clinic experience. *J Pediatr Hematol Oncol* 2009;31(07):522–526
- 14 Enjolras O, Wassef M, Mazoyer E, et al. Infants with Kasabach-Merritt syndrome do not have “true” hemangiomas. *J Pediatr* 1997;130(04):631–640
- 15 Kasabach HH. Capillary hemangioma with extensive purpura: report of a case. *Am J Dis Child* 1940;59(05):1063
- 16 Maguiness S, Guenther L. Kasabach-Merritt syndrome. *J Cutan Med Surg* 2002;6(04):335–339
- 17 Neidhart JA, Roach RW. Successful treatment of skeletal hemangioma and Kasabach-Merritt syndrome with aminocaproic acid. Is fibrinolysis “defensive”? *Am J Med* 1982;73(03):434–438
- 18 Hurley MC, Gross BA, Surdell D, et al. Preoperative Onyx embolization of aggressive vertebral hemangiomas. *AJNR Am J Neuro-radiol* 2008;29(06):1095–1097