





Acute Appendicitis in Children with Hematological Malignancies: The Need for Early Diagnosis and Prompt Treatment—A Single-Center Case Series

Shruti Kakkar¹  Arihant Jain²  Evani Jain³ Anubhav Gupta⁴ Navneet Kaur¹ Anirudh Jain³
Alka Grewal² Sushil Budhiraja² Chandan Kakkar⁵

¹Department of Pediatrics, Dayanand Medical College and Hospital, Ludhiana, Punjab, India

²Department of Pediatric Surgery, Dayanand Medical College and Hospital, Ludhiana, Punjab, India

³MBBS, Dayanand Medical College and Hospital, Ludhiana, Punjab, India

⁴Department of Surgery, Dayanand Medical College and Hospital, Ludhiana, Punjab, India

⁵Department of Radiodiagnosis, Dayanand Medical College and Hospital, Ludhiana, Punjab, India

Address for correspondence Shruti Kakkar, MBBS, MD, Department of Pediatrics, Dayanand Medical College and Hospital, Ludhiana 141001, Punjab, India (e-mail: drahuashruti@gmail.com).

Ind J Med Paediatr Oncol 2024;45:402–409.

Abstract

Introduction Appendicitis in patients with hematological malignancies presents with vague symptoms, thus requiring a high degree of suspicion for early diagnosis and treatment to prevent complications.

Objectives The aim of this article was to describe the demographic, clinicoradiological, operative findings, and outcomes in patients with acute appendicitis with underlying hematological malignancies.

Materials and Methods A retrospective review of pediatric patients with hematological malignancy who developed acute appendicitis was conducted. Medical records of patients were reviewed for patient demographics, disease status, signs, and symptoms at the time of diagnosis of acute appendicitis, and outcome. The laboratory, radiological, and histological findings were retrieved from the hospital records.

Results Six (2.4%) patients developed acute appendicitis over the past 8 years among a total of 254 patients treated for hematological malignancies in the unit. Five patients had underlying acute lymphoblastic leukemia (ALL) and one had acute myeloid leukemia (AML). Of the five patients, three were in postremission consolidation, one each in the delayed intensification and maintenance phase of chemotherapy. The child with AML was on induction chemotherapy for the first relapse at the time of diagnosis. Fever and abdominal pain were the common presenting symptoms. Diagnosis was made on ultrasound abdomen in five patients, and one patient was diagnosed on computed tomography. All patients underwent open appendectomy. Two patients had evidence of appendiceal perforation. Three patients had neutropenia at the time of developing appendicitis and underwent appendectomy regardless of the absolute neutrophil count (ANC). Five patients recovered well, and chemotherapy was restarted within 2 weeks of appendectomy. One

Keywords

- ▶ acute appendicitis
- ▶ hematological malignancies
- ▶ neutropenia

article published online
May 24, 2024

DOI <https://doi.org/10.1055/s-0044-1786679>.
ISSN 0971-5851.

© 2024. The Author(s).

This is an open access article published by Thieme under the terms of the Creative Commons Attribution License, permitting unrestricted use, distribution, and reproduction so long as the original work is properly cited. (<https://creativecommons.org/licenses/by/4.0/>)

Thieme Medical and Scientific Publishers Pvt. Ltd., A-12, 2nd Floor, Sector 2, Noida-201301 UP, India

patient developed a superficial surgical site infection. and one patient with relapsed AML expired due to refractory septic shock.

Conclusion Acute appendicitis in patients with hematological malignancies can present with subtle signs and symptoms. Appendectomy can be safely performed irrespective of the ANC.

Introduction

The gastrointestinal tract is one of the most common sources of infective complications in children with hematological malignancies, with a specific predilection to the ileocecal region. Acute appendicitis is the most common surgical emergency in children with a lifetime cumulative incidence rate of 9% in the general population. Younger children are at an increased risk of complicated appendicitis.^{1,2} The reported incidence of appendicitis is as low as 0.5% in children with leukemia and most children present with vague abdominal signs requiring a high index of suspicion for early diagnosis and treatment. The presence of neutropenia and/or thrombocytopenia, along with underlying disease conditions, has led to controversy over whether to opt for medical or surgical management in these patients.^{3,4} Here we present the data of six children with underlying hematological malignancy managed for acute appendicitis at our center.

Materials and Methods

Study Design

A retrospective observational study was conducted in the Pediatric Hematology Oncology unit of the Department of Pediatrics, Dayanand Medical College and Hospital, Ludhiana.

Sample Size

All pediatric patients undergoing treatment for a hematological malignancy who developed acute appendicitis from August 2014 to December 2022 were included in the study. The data regarding the patient's age, gender, anthropometry, underlying disease status, signs and symptoms, laboratory, radiological, and histopathological data, treatment modalities, and outcomes at the time of development of acute appendicitis were retrieved from the hospital records. The diagnosis of acute appendicitis was made radiologically on an ultrasound (US) or computed tomography (CT) scan in the presence of blind-ending incompressible tubular structure in the right lower quadrant with an overall diameter of more than 6 mm and raised echogenicity of surrounding mesenteric fat.⁵ It may or may not be associated with free fluid or abscess in the abdominal cavity.

The patients with ALL are treated as ALL-BFM 1995 protocol and patients with acute myeloid leukemia (AML) receive one to two courses of (7 + 3) induction followed by three courses of high-dose cytarabine.^{6,7}

Inclusion and Exclusion Criteria

All patients less than 18 years of age who developed acute appendicitis while on treatment for an underlying

hematological malignancy were included in the study. Non-availability of data/incomplete data regarding any of the studied variables was considered an exclusion criterion.

Primary and Secondary Outcomes

Primary Outcome

Outcome of patients with hematological malignancies who developed acute appendicitis.

Secondary

- A) To describe clinical, laboratory, and radiological findings.
- B) To describe the operative findings.
- C) The time taken to start oral feed/duration of hospital stay.
- D) The time taken to reinstitute chemotherapy.

Statistical Analysis

The data collected was tabulated in Excel sheets and statistical analysis was performed using descriptive methods. Data were described in terms of range; mean \pm standard deviation (\pm standard deviation), frequencies (number of cases), and relative frequencies (percentages) as appropriate.

Results

Over a period of 8 years, 254 children were treated for hematological malignancies and six of them developed acute appendicitis (2.4%) during the treatment. Among the six patients diagnosed with appendicitis, five had an underlying diagnosis of ALL, and only one had AML. The median age at the time of diagnosis of appendicitis was 7.5 years (range: 4–15 years). All patients were male. Of the five ALL patients, three were in the postremission consolidation phase, one was in the delayed intensification phase, and one patient was on maintenance chemotherapy. The sixth patient with AML was on induction chemotherapy for the first relapse (**Table 1**).

Three patients had neutropenia at the time of surgery, with absolute neutrophil count (ANC) being as low as 10 cells/ μ L in the patient with relapsed AML. The median ANC at the time of admission and surgery was 847.5 cells/ μ L (range: 10–7,040 cells/ μ L) and 1,299.5 cells/ μ L (range: 10–7,921 cells/ μ L), respectively. The median hemoglobin and median platelet count at the time of surgery were 9g/dL and 133,500 cells/ μ L, respectively with thrombocytopenia in two patients.

All patients had a fever, five had abdominal pain, and four patients had classical tenderness at the right lower quadrant

Table 1 Demographic details, duration of symptoms, and laboratory findings of leukemic children with acute appendicitis

Patient no.	1	2	3	4	5	6
Age in years	9	4	15	7	8	7
Gender	Male	Male	Male	Male	Male	Male
Weight (kg) and Z score as per CDC weight for age.	25 (-0.9)	17 (0.34)	30 (-4.33)	23 (-0.05)	25 (-0.19)	19.7 (-1.22)
Height (cm) and Z score as per CDC height for age.	128 (-0.9)	107 (1.1)	157 (-1.6)	121 (-0.2)	125 (-0.5)	115 (-1.3)
Diagnosis	Pre-B ALL	Pre-B ALL	Pre-B ALL	Pre-B ALL	Pre-B ALL	Relapsed AML
Disease status	Remission	Remission	Remission	Remission	Remission	Relapse
Phase of treatment	Delayed intensification	Consolidation	Consolidation	Consolidation	Maintenance	Reinduction
Duration of symptoms before surgery (days)	2	2	2	18	7	7
ANC at admission (cells/ μ L)	1,278	1,239	456	7,040	140	10
ANC at surgery (cells/ μ L)	4,268	2,059	540	7,921	480	10
Platelet count at admission (cells/ μ L)	4,00,000	1,10,000	2,04,000	3,21,000	15,000	15,000
Platelet count at surgery (cells/ μ L)	1,17,000	2,28,000	1,50,000	7,19,000	31,000	11,000
Hemoglobin at admission (g/dL)	11.6	8.6	7.6	9.7	8.2	8.7
Hemoglobin at surgery (g/dL)	7.9	8.7	9.3	8.1	9.6	9.7

Abbreviations: ALL, acute lymphoblastic leukemia; AML, acute myeloid leukemia; ANC, absolute neutrophil counts; CDC, Centers for Disease Control and Prevention.

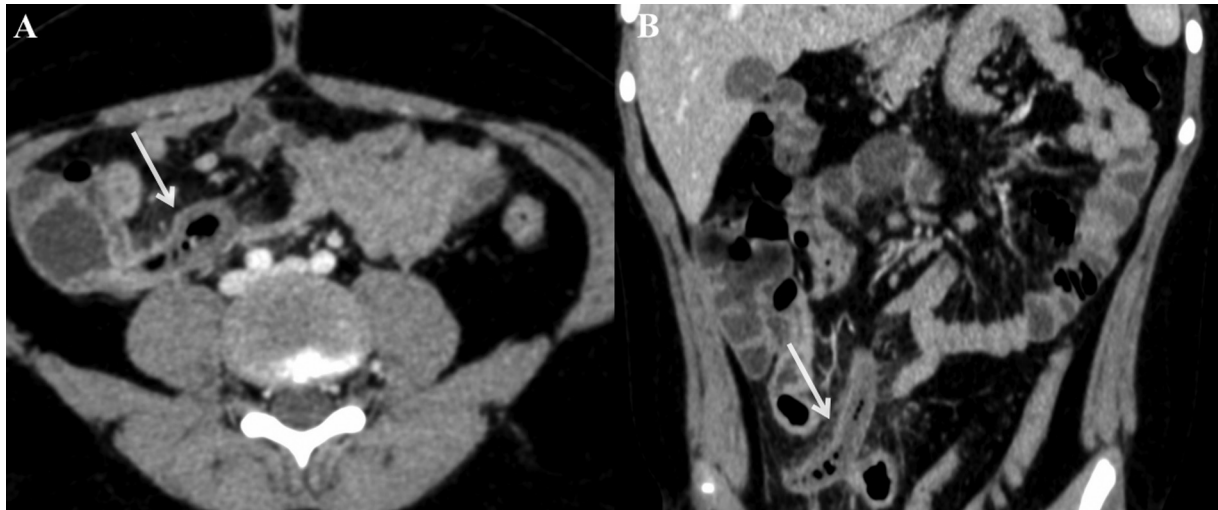


Fig. 1 (A, B) Axial and coronal postcontrast images showing a dilated appendix (arrow) in the right iliac fossa with significant peri-appendiceal fat stranding in keeping with acute appendicitis.

of the abdomen. Three patients were diagnosed with acute appendicitis within 24 hours of the onset of signs and symptoms and underwent emergency appendectomy after stabilization. Two patients had a delay in diagnosis due to the absence of signs of tenderness in the right lower quadrant and one of them required a CT scan (► **Fig. 1**) to establish the diagnosis preoperatively. Another patient was being managed for febrile neutropenia and did not have any localizing signs. An US abdomen done to determine the focus for persistent fever revealed peri-appendicular echogenic collection. The collection was drained by US-guided percutaneous technique, and an interval appendectomy was performed 2 weeks later. At the time of admission, all patients were started on broad-spectrum antibiotics (cefoperazone/sulbactam and amikacin) as per febrile neutropenia protocol. Oral feeds were withheld once diagnosed with appendicitis and patients were administered maintenance intravenous fluids. Paracetamol was used for the management of pain in all patients. All children underwent open appendectomy. The antibiotics were modified in the patient who underwent percutaneous drainage based upon the pus culture and sensitivity pattern. The pus culture showed growth of *Klebsiella pneumoniae* sensitive to carbapenems. Four patients required transfusion of blood components perioperatively. Two patients had developed complicated appendicitis in the form of appendicular perforation. One patient developed a superficial surgical site infection that was managed by regular bedside wound care. One of the patients had a coexistent coronavirus 2019 infection at the time of diagnosis of appendicitis but did not affect the surgical intervention or outcome.

Five patients recovered well and were started on an oral diet at a mean duration of 35 hours after surgery (range: 24–48 hours). Chemotherapy was restarted after a mean duration of 11.2 days (4–17 days) from the onset of symptoms. Patients were discharged after a mean postoperative

stay of 7 days (range: 5–10 days). One patient had a delay in diagnosis due to inconclusive US findings. The patient had persistent fever with neutropenia on day 4 of admission; hence, antibiotics were upgraded, and antifungal therapy was added empirically as per the institutional policy. A CT scan conducted on day 5 due to clinical worsening and development of abdominal distension revealed the presence of appendicular perforation, which necessitated surgical intervention. The patient developed features of septic shock on postoperative day 4 requiring inotropic (norepinephrine and dobutamine infusion) support and died on postoperative day 8 due to refractory septic shock (► **Table 2**). All six patients had histology-proven appendicitis with no specimen showing leukemic infiltration on hematoxylin-eosin staining and immunohistochemistry (► **Fig. 2**).

Discussion

Acute appendicitis is a rare gastrointestinal complication in children being treated for hematological cancers. The reported incidence of acute appendicitis in children with hematological malignancy is 0.5 to 4.5% as shown in multiple studies (► **Table 3**).^{8–10} This study revealed an incidence rate of 2.4% among these children (► **Table 3**). There are multiple causes of the acute surgical abdomen in children undergoing treatment for leukemia but the most common are acute appendicitis and typhlitis.⁹ Typhlitis is characterized by the cecal or terminal ileal wall thickness of more than 3 mm on US for a variable length of the bowel segment. Mucosal injuries from chemotherapy, bacterial overgrowth, and neutropenia contribute to typhlitis.¹¹ The most probable etiology of appendicitis in children with leukemia is luminal obstruction by a fecolith, which is similar to patients with appendicitis in the general population. Other causes of appendicitis may include lymphoid hyperplasia secondary to a viral infection, enterocolitis in a neutropenic patient, or

Table 2 Image findings, operative,^a and pathological findings with postoperative details and outcomes

Patient no.	Radiological findings	Operative findings	HPE findings	Time taken to initiate oral soft diet (days)	Time taken to restart chemotherapy (days)	Postoperative hospital stay (days)	Outcome	Perioperative complications
1	Dilated inflamed appendix (caliber 7 mm)	Retrocecal inflamed appendix	Acute appendicitis	1	17	4	Recovered	None
2	Inflamed edematous appendix (12 mm) Raised peri-appendiceal echogenicity	Retrocecal inflamed appendix	Acute appendicitis	1	10	6	Recovered	None
3	Inflamed edematous appendix (6.7 mm) Raised peri-appendiceal echogenicity (subhepatic location)	Retrocecal inflamed appendix with the tip in subhepatic region	Acute appendicitis	2	14	6	Recovered	Superficial surgical site
4	Dilated appendix with peri-appendiceal collection (4.7 × 6.6 cm) ^b	Retrocecal appendix with sloughed-off tip Densely adherent omentum in right iliac fossa & pelvis	Acute suppurative appendicitis	2	10	10	Recovered	None
5	Inflamed edematous appendix (10 mm) raised peri-appendiceal echogenicity	5 cm long appendix, retrocecal in location Distal 2/3 inflamed and edematous	Acute appendicitis	1	7	5	Recovered	None
6	No signs of inflammation on US ^c	Inflamed retrocecal appendix wrapped in the omentum Inflamed ileocecal junction	Acute gangrenous appendicitis	Not started	Not started	8	Expired	Septic shock

Abbreviations: CECT, contrast-enhanced computed tomography; HPE, histopathological examination.

^aAll patients underwent open appendicectomy.

^bUltrasound-guided drainage of purulent contents.

^cFindings on CECT abdomen: Inflamed appendix with a maximum diameter of over 6mm.

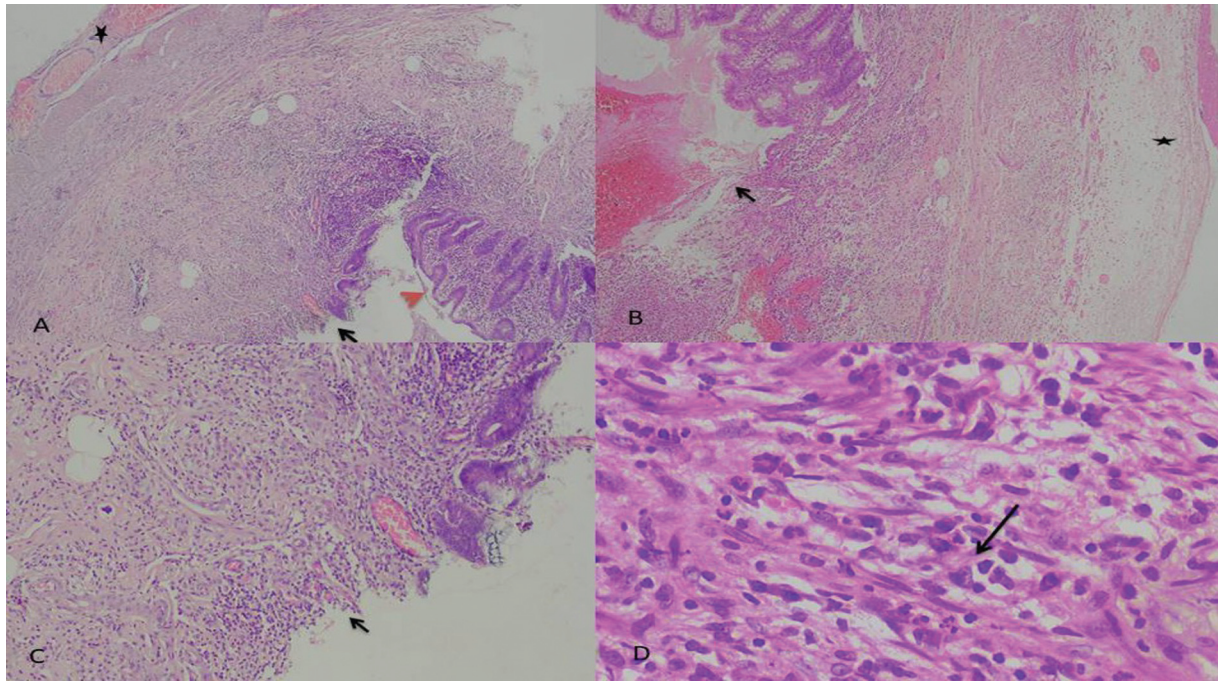


Fig. 2 Histopathological examination of the surgical specimen. (A, B) Scanner view showing mucosal ulceration (black arrow) with transmural infiltration by neutrophils along with serosal congestion in two different areas shown with normal mucosa (orange arrowhead; hematoxylin and eosin [H&E] 40X). (C) Low power view showing ulceration of mucosa (black arrow; H&E 100X). (D) High-power view showing the presence of neutrophils (black arrow) in muscularis propria of appendix (H&E 400X).

leukemic infiltration of the appendix. The incidence of leukemic infiltration of the appendix is negligible as shown by others; none of the patients had leukemic infiltration of appendix in our cohort (►Table 3).^{12–14} It is difficult to diagnose appendicitis in immune-compromised patients with leukemia due to the absence of typical signs and symptoms.^{8,9,15} Timely diagnosis of appendicitis is key to improving overall survival in these children.¹⁶ Several studies have confirmed that US and contrast-enhanced CT aid in establishing the diagnosis for this group of children as highlighted in ►Table 3.^{4,9,17,18} In our cohort, US successfully diagnosed appendicitis in all patients except for one, who later underwent a CT scan for confirmation.

A debate continues between surgical and nonsurgical approaches to treat appendicitis in leukemic children. Appendectomy has been the mainstay of management of acute appendicitis in the past. There is emerging data that nonoperative management with broad-spectrum antibiotics may be equally effective and safe for the management of uncomplicated acute appendicitis. The complications of early surgery may include blood loss, bowel obstruction, injury to bowel wall or surrounding tissues, abscess/fistula formation, dissemination of infection, and wound complications. The management of complicated acute appendicitis, that is, presence of perforation or abscess formation, remains controversial.^{1,2}

Many studies till the late 1970s showed that patients managed medically had poor outcomes.¹⁹ Exelby et al and Ver Steeg et al advocated early surgical intervention that improved survival by 50% in these children.^{20,21} The distorted anatomy of inflamed tissues in delayed surgical

interventions raises concerns about a higher risk of perioperative complications. Delaying surgical resection may also increase the risk of progression and recurrence of complicated appendicitis.²² Park et al recommended a non-surgical approach in the initial stages till the ANC improves.⁵ Patients with persistent symptoms after an increase in ANC or sudden worsening were recommended surgery. Neutropenic children with acute appendicitis should be treated medically without surgery, according to Wiegering et al.⁴ All five children recovered well in their study, and none developed recurrent appendicitis. In our institute, all children independent of the ANC at the time of diagnosis undergo early appendectomy, which reduces the recovery time postoperatively. At the time of surgery, three of our patients had moderate-to-severe neutropenia, reinforcing the feasibility of appendectomy in neutropenic patients. Mortellaro et al demonstrated that an early appendectomy (within 24 hours of the onset of symptoms) is safe in neutropenic patients and did not result in an increased risk of infections or mortality during the perioperative period.^{19,22}

We believe that delay in recovery from infection can lead to the interruption of chemotherapy for the underlying disease. This can lead to ineffective treatment and hence increase the chances of relapse in the future. Upfront appendectomy in children with leukemia resulted in fewer complications, shorter hospital stay, and fewer delays in chemotherapy completion in a retrospective review by Many et al.³ Either of the two approaches (open or laparoscopic appendectomy) can be followed based on the patient's disease status and surgeon's preferences with no significant differences in the outcome.³

Table 3 Details of various studies comparing study details of a similar group of patients

Study/ year	Study center	Total patients	No. of patients with appendicitis	Underlying diagnosis			Treatment		Leukemic infiltration on HPE	Outcome		
				ALL	AML	Others	Medical	Appendectomy		Recovered	Mortality	Complications
Ver Steeg et al, 1979 ²¹	Multicenter	NK	5	4	1	0	0	1	0	1	1	2
Angel et al, 1992 ⁹	Single	2794	14	10	4	0	1	8+5 ^a	None	11	3	0
Hobson et al, 2005 ¹⁷	NK	464	7	5	1	1	0	6	None	7	0	0
Wiegering et al, 2008 ⁴	Single	113	5	1	3	1	5	0	Unknown	5	0	0
Mortellaro et al, 2011 ²²	Multicenter	NK	10	5	4	1	0	10	Unknown	9	1	0
Kim et al, 2012 ¹⁰	Single	1209	7	3	4	0	0	2	None	7	0	0
Warad et al, 2015 ¹²	Single	154	3	1	2	0	0	2	1	2	0	1
Wang et al, 2019 ¹⁴	Single	NK	23	3	2	18	0	17	2	22	1	9
Von Mersi et al, 2021 ¹³	Single	2341	21(23 episodes)	Acute leukemia 15	6	0	0	15	1	1	1	
This study	Single	254	6	5	1	0	0	6	None	5	1	

Abbreviations: ALL, acute lymphoblastic leukemia; AML, acute myeloid leukemia; HPE, histopathological examination; NK, not known.
^aAppendectomy and drainage—5, Appendectomy—8.

This study is an attempt to demonstrate the course of appendicitis in children with underlying malignancy at our institution. This study can guide the management of appendicitis in children with leukemia in a resource-constrained setting; however, it has several limitations. This is a retrospective study and the number of patients is small. The nutritional status of children as indicated by serum albumin levels should have been taken into account to correlate outcomes in this respect. We did not measure C reactive protein levels which may have helped in prognostication in this subset.

Conclusion

Acute appendicitis being the most common surgical emergency in children with hematological malignancies must always be suspected in a child presenting with persistent fever and/or pain abdomen. Diagnosing appendicitis in this subset requires good clinical and radiological acumen. Appendectomy can be safely performed in patients irrespective of neutropenia/thrombocytopenia with optimal supportive care.

Ethical Statement

Ethics approval has been obtained with their letter number DMCH/IEC/2023/216 dated 18/7/2023. All procedures performed in studies involving human participants were in accordance with the ethical standards of the institutional and/or national research committee and with the 1964 Helsinki Declaration and its later amendments or comparable ethical standards mentioned in the Helsinki Declaration.

Authors' Contributions

S.K., S.B., and A.G. conceptualized the study. S.K., S.B., A.G., and A.J. designed the study. S.K., S.B., A.G., A.J., C.K., and A.G. contributed to definition of intellectual content. A.G., C.K., E.J., A.J., and N.K. helped in literature search. S.K., S.B., A.G., A.J., A.G., C.K., E.J., An.J., and N.K. were involved in clinical studies and manuscript review. E.J., An.J., and N.K. were involved in data acquisition, data analysis, statistical analysis, and manuscript editing. A.G., E.J., An.J., and N.K. contributed to manuscript preparation.

Patient's/Guardian's Consent

Not applicable.

Source of Support

None.

Conflict of Interest

None declared.

Acknowledgments

None.

References

- Almaramby HH. Acute appendicitis in young children less than 5 years: review article. *Ital J Pediatr* 2017;43(01):15
- Zavras N, Vaos G. Management of complicated acute appendicitis in children: still an existing controversy. *World J Gastrointest Surg* 2020;12(04):129–137
- Many BT, Lautz TB, Dobrozsi S, et al; PEDIATRIC SURGICAL ONCOLOGY RESEARCH COLLABORATIVE. Appendectomy versus observation for appendicitis in neutropenic children with cancer. *Pediatrics* 2021;147(02):e2020027797
- Wiegering VA, Kellenberger CJ, Bodmer N, et al. Conservative management of acute appendicitis in children with hematologic malignancies during chemotherapy-induced neutropenia. *J Pediatr Hematol Oncol* 2008;30(06):464–467
- Park NH, Oh HE, Park HJ, Park JY. Ultrasonography of normal and abnormal appendix in children. *World J Radiol* 2011;3(04):85–91
- Möricke A, Reiter A, Zimmermann M, et al; German-Austrian-Swiss ALL-BFM Study Group. Risk-adjusted therapy of acute lymphoblastic leukemia can decrease treatment burden and improve survival: treatment results of 2169 unselected pediatric and adolescent patients enrolled in the trial ALL-BFM 95. *Blood* 2008;111(09):4477–4489
- Gibson BES, Wheatley K, Hann IM, et al. Treatment strategy and long-term results in paediatric patients treated in consecutive UK AML trials. *Leukemia* 2005;19(12):2130–2138
- Hsiao PJ, Kuo SM, Chen JH, et al. Acute myelogenous leukemia and acute leukemic appendicitis: a case report. *World J Gastroenterol* 2009;15(44):5624–5625
- Angel CA, Rao BN, Wrenn E Jr, Lobe TE, Kumar AP. Acute appendicitis in children with leukemia and other malignancies: still a diagnostic dilemma. *J Pediatr Surg* 1992;27(04):476–479
- Kim EY, Lee JW, Chung NG, Cho B, Kim HK, Chung JH. Acute appendicitis in children with acute leukemia: experiences of a single institution in Korea. *Yonsei Med J* 2012;53(04):781–787
- McCarville MB, Adelman CS, Li C, et al. Typhlitis in childhood cancer. *Cancer* 2005;104(02):380–387
- Warad D, Kohorst MA, Altaf S, et al. Acute appendicitis in acute leukemia and the potential role of decitabine in the critically ill patient. *Leuk Res Rep* 2015;4(01):21–23
- von Mersi H, Benkö T, Boztug H, et al. Diagnosis and management of acute appendicitis in 21 pediatric hematology and oncology patients at a tertiary care cancer center. *Sci Rep* 2021;11(01):12170
- Wang C, Huang H-Z, Yu Y-J, Han SL. Acute appendicitis in patients with leukemia: a dilemma in diagnosis and surgical treatment OPEN ACCESS citation. *Remedy Publications LLC, J. Clinics in Surgery* 2019;4:2433<http://clinicsinsurgery.com/> Accessed August 23, 2023
- Sbragia Neto L, Oliveira-Filho AG, Epelman S, Koeller HF, Bustorff-Silva JM, Brandalise SR. Selective surgical indication in the management of neutropenic children presenting with acute abdomen. *Pediatr Hematol Oncol* 2000;17(06):483–487
- Kim KU, Kim JK, Won JH, Hong DS, Park HS. Acute appendicitis in patients with acute leukemia. *Korean J Intern Med (Korean Assoc Intern Med)* 1993;8(01):40–45
- Hobson MJ, Carney DE, Molik KA, et al. Appendicitis in childhood hematologic malignancies: analysis and comparison with typhlitis. *J Pediatr Surg* 2005;40(01):214–219, discussion 219–220
- Ozyurek E, Arda S, Ozkiraz S, Alioglu B, Arikan U, Ozbek N. Febrile neutropenia as the presenting sign of appendicitis in an adolescent with acute myelogenous leukemia. *Pediatr Hematol Oncol* 2006;23(03):269–273
- Wade DS, Douglass H Jr, Nava HR, Piedmonte M. Abdominal pain in neutropenic patients. *Arch Surg* 1990;125(09):1119–1127
- Exelby PR, Ghandchi A, Lansigan N, Schwartz I. Management of the acute abdomen in children with leukemia. *Cancer* 1975;35(03):826–829
- Ver Steeg K, LaSalle A, Ratner I. Appendicitis in acute leukemia. *Arch Surg* 1979;114(05):632–633
- Mortellaro VE, Juang D, Fike FB, et al. Treatment of appendicitis in neutropenic children. *J Surg Res* 2011;170(01):14–16