




Primary, Nonmidline, Extragonadal, Immature Teratoma of the Palm with Axillary Nodal Metastasis: A Rare Case Report and Review of Literature

Reshma R. Balachandran¹ Vishesha V. Adhvaryu² Shalaka Joshi¹ Mukta Ramadwar²
Ameya Bindu³ Prakash Nayak¹

¹Department of Surgical Oncology, Tata Memorial Centre and Homi Bhabha National Institute, Mumbai, Maharashtra, India

²Department of Pathology, Tata Memorial Centre and Homi Bhabha National Institute, Mumbai, Maharashtra, India

³Department of Plastic and Reconstructive Surgery, Tata Memorial Centre and Homi Bhabha National Institute, Mumbai, Maharashtra, India

Address for correspondence Shalaka Prakash Joshi, MS, MCh, MRes, Department of Surgical Oncology, Tata Memorial Hospital and Homi Bhabha National Institute, Room no 1207, Homi Bhabha Building, Dr E Borges Road, Parel, Mumbai, Maharashtra, 400012, India (e-mail: drjoshishalaka@gmail.com).

Ind J Med Paediatr Oncol

Abstract

Primary, nonmidline, extragonadal germ cell tumors are rare. Numerous hypotheses have been proposed regarding their origin. There is lack of consensus regarding their appropriate management. We report a case of an immature teratoma arising of the left palm. A 36-year-old lady presented with a recurrent left palm swelling. Histopathological features with immunohistochemical evaluation were characteristic of an immature teratoma. Alpha-fetoprotein (AFP) and lactate dehydrogenase (LDH) were elevated. She received preoperative chemotherapy with bleomycin, etoposide, cisplatin (BEP) followed by wide excision of the palm lesion and reconstruction with free latissimus dorsi flap. Postoperatively, two more cycles of BEP were given. Eight months later, she presented with large left axillary mass which showed metastatic deposits of immature teratoma on trucut biopsy. AFP and LDH were mildly elevated. On staging fluorodeoxyglucose-positron emission tomography (FDG-PET), there were no distant metastases. She received two cycles of vinblastine, ifosfamide, and cisplatin (VeIP). Postchemotherapy FDG-PET showed good metabolic response; however, the mass remained morphologically stable. Complete resection of the axillary mass was achieved with resection of a segment of axillary vein and end-to-end reanastomosis. At 12 months of follow-up the patient is disease free. This is the first report of axillary metastases in immature teratoma of the upper extremity. Axilla is a possible site of lymph node metastases in extremity teratoma. Primary extragonadal germ cell tumor should be managed with complete surgical resection and chemotherapy.

Keywords

- ▶ teratoma
- ▶ extragonadal germ cell tumor
- ▶ nonmidline axillary teratoma
- ▶ soft tissue teratoma

DOI <https://doi.org/10.1055/s-0043-1776343>.
ISSN 0971-5851.

© 2023. The Author(s).

This is an open access article published by Thieme under the terms of the Creative Commons Attribution License, permitting unrestricted use, distribution, and reproduction so long as the original work is properly cited. (<https://creativecommons.org/licenses/by/4.0/>)
Thieme Medical and Scientific Publishers Pvt. Ltd., A-12, 2nd Floor, Sector 2, Noida-201301 UP, India

Introduction

Extragenadal germ cell tumors (GCTs) are characteristically situated in midline without any gonadal involvement. The most common sites are the mediastinum, retroperitoneum, and central nervous system.¹ The classic theory of their origin is from germ cell precursors arrested during midline migration at embryogenesis. Nonmidline extragenadal primary GCTs are extremely rare. Extremity is an even rare site of occurrence as it does not come in the embryological pathway of migration of primordial germ cells. This lowers the index of suspicion and makes the diagnosis of extremity GCTs challenging. Striking histopathological features corroborated with specific immunohistochemical (IHC) markers aid diagnosis.

Only seven cases have been reported in literature so far (►Table 1).²⁻⁸ Few reported sites of extremity GCT are arm,⁵ thigh,^{6,7} humerus,⁴ iliac bone,³ and sole of the foot.² Various hypotheses have been proposed regarding their possible origin, but none have been conclusive. Little is known regarding the real nature of the origin of this unusual presentation and there is lack of guidelines regarding management. There is no reported case of axillary lymph node involvement in an upper extremity teratoma. We describe a case of a 36-year-old lady with immature teratoma of left palm which was managed by chemotherapy followed by negative margin excision and reconstruction. Later she presented with axillary nodal metastasis which was managed by second-line chemotherapy followed by curative resection.

Case Report

A 36-year-old lady presented with an ulcero-fungating left palm swelling. She had an unplanned excision biopsy elsewhere before presenting to us with a 8 × 6 cm mass overlying the left hypothenar eminence extending up to thenar region (►Fig. 1A). A diagnostic wedge biopsy was suggestive of a malignant tumor exhibiting tissues derived from all three germ cell layers in the form of glandular epithelial structures,

islands of squamous epithelium and immature cartilage, and immature spindle cell mesenchymal tissue with conspicuous amount of immature neuroepithelium. This was diagnostic of immature teratoma Norris grade 3. On IHC, epithelial component was highlighted by AE1/AE3, cartilaginous tissue by S100, and immature neuroepithelium by synaptophysin (►Fig. 1D-F).

SALL4 marked several tumor cells across all cell lineages. Serum alpha-fetoprotein (AFP) (26.24 ng/mL) and lactate dehydrogenase (LDH) (230 U/L) were mildly elevated and beta-human chorionic gonadotropin was normal. A staging fluorodeoxyglucose-positron emission tomography (18-FDG-PET) showed hypermetabolic ulceroproliferative exophytic soft tissue mass involving the lateral aspect of the palmar surface of the left hand (maximum standardized uptake value [SUVmax] 27.83) with few FDG avid enlarged left axillary nodes (SUVmax 14.68). Axillary ultrasound and guided fine-needle aspiration cytology from the left axillary node was negative. Magnetic resonance imaging of the hand showed mass toward the ventral aspect involving the hypothenar eminence (►Fig. 1B, C). As per multidisciplinary meeting (MDM) discussion, she received BEP (bleomycin, etoposide, cisplatin) chemotherapy. Following three cycles, she had partial response with residual swelling in the left palm. She underwent negative margin excision which included sacrifice of the tendon of palmaris longus, flexor carpi ulnaris, ulnar vessels, and part of ulnar nerve which was traversing through the tumor. The defect was reconstructed using free latissimus dorsi (LD) muscle flap and split thickness skin graft over it. The 5-cm ulnar nerve defect was restored using the thoracodorsal nerve (motor nerve of LD) as a graft. Final histopathology was residual viable immature teratoma with free margins. It confirmed the same histological and IHC findings as the diagnostic biopsy. She then received two cycles of adjuvant BEP chemotherapy.

After a disease-free interval of 8 months, she presented with left axillary swelling 15 × 10 cm size (►Fig. 2A). FDG-PET-contrast-enhanced computed tomography (CECT)

Table 1 Cases of immature teratoma in extragenadal extremities reported in literature till date

Study, year	Age, gender	Site of presentation	Metastasis, time interval from diagnosis	Management
Chinoy et al, 1992 ²	27, male	Sole of foot	Yes, groin node at diagnosis	Surgery
Vazquez et al, 2000 ³		Iliac bone	No (previous history of neck teratoma)	Chemotherapy
Koh et al, 2009 ⁴	14, female	Proximal humerus	No	Surgery
Ait Benali et al, 2012 ⁵	37, male	Arm	Yes, axillary node at presentation	4#BEP chemotherapy + surgery (wide excision + axillary clearance) + 2#BEP
Zuquello et al, 2016 ⁶	27, male	Thigh	No	Surgery (wide excision) + 4#BEP + TIP chemotherapy
Coli et al, 2019 ⁷	86, female	Thigh	No	Surgery
Rajpoot et al, 2020 ⁸	35, female	Palm	No	Excision biopsy

Abbreviations: BEP, bleomycin, etoposide, cisplatin; TIP, taxanes, ifosfamide, cisplatin.

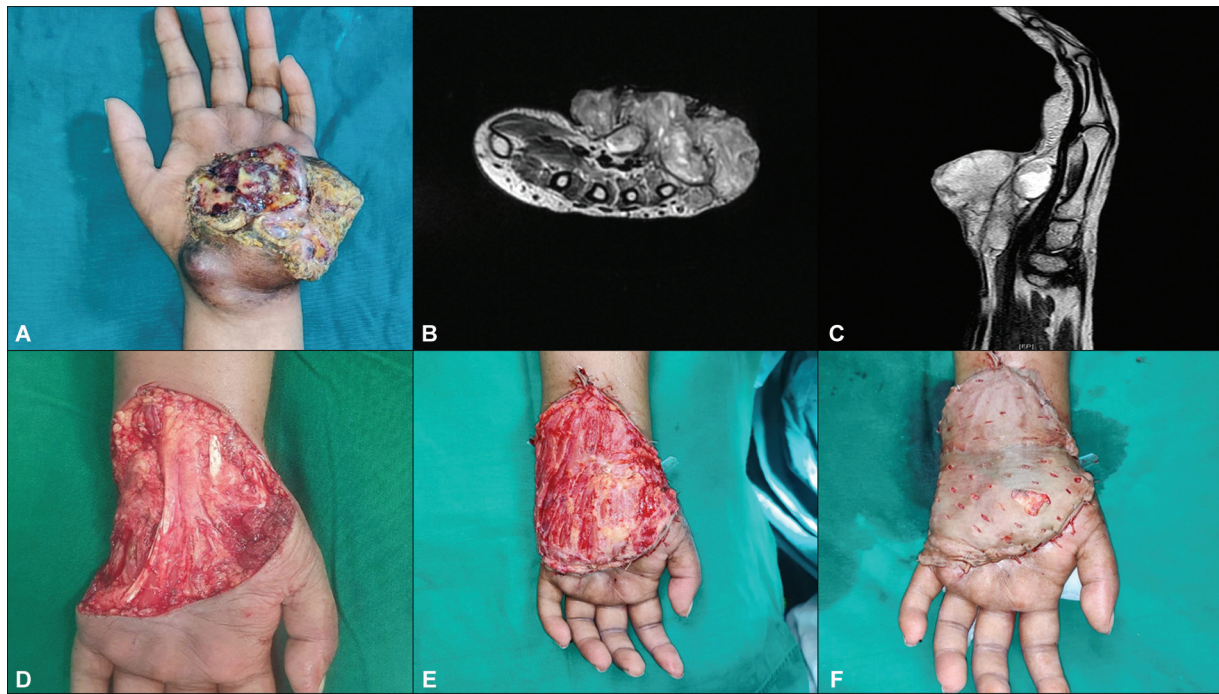


Fig. 1 Presentation of left palm teratoma. (A) Ulcero-fungating mass on the left palmar surface. (B) Magnetic resonance imaging (MRI) image—axial T2 contrast cuts showing the proliferative mass near hypothenar eminence. (C) MRI image—sagittal T2 cuts showing the mass toward ventral aspect. Histological features showing (D) immature neuroepithelium in the form of neuroepithelial rosettes (neuroectodermal derivative) along with immature mesenchyme seen as primitive, loose mesenchymal tissue (mesodermal derivative). (E) Immature mesenchyme along with smooth muscle (mesodermal derivative). (F) Mature glandular tissue showing ciliated columnar epithelium with goblet cells (endodermal derivative).

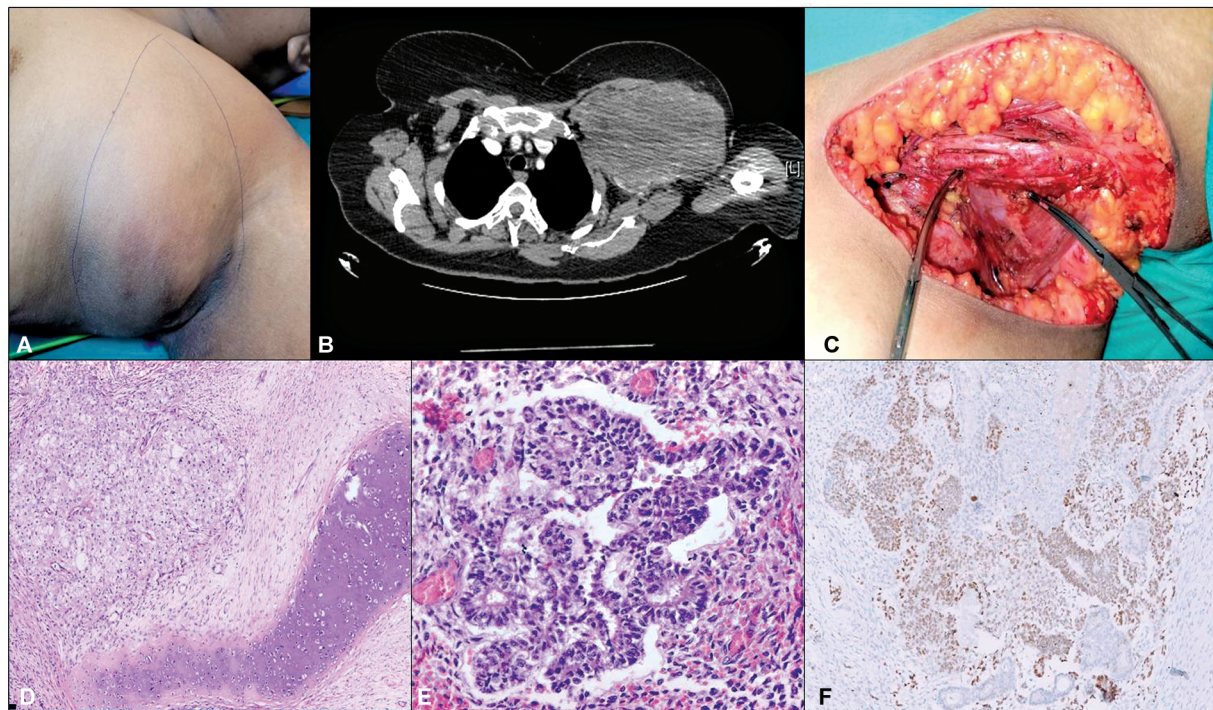


Fig. 2 Presentation of left axillary recurrence. (A) Left axilla 10 × 10 cm mass. (B) Computed tomography (CT) axial image showing the bulky axillary mass abutting the vessels. (C) Surgical resection image showing axillary bed after excision of the mass with axillary vein segmental resection (2 vascular clamps). (D) Histological feature showing immature cartilage on the right and epithelial elements on the left. (E) Immature neuroepithelium forming rosettes. (F) Immunoreactivity for SALL4.

showed 9.8×6.6 cm left axillary soft tissue nodal mass (SUVmax 11.90) with no disease elsewhere. Tumor markers were mildly elevated. Serum AFP was 18.93 (0.89–8.78 ng/mL) and LDH was 273 (100–193 U/L). As per MDM, two cycles of VeIP (vinblastine, ifosfamide, and cisplatin) were administered. Repeat FDG-PET showed significant decrease in SUV (SUVmax 4.09); however, morphological size remained the same. CT thorax showed ill-defined heterogeneously enhancing left axillary nodal mass measuring $15.7 \times 10.7 \times 10$ cm with indistinct fat planes with pectoral, supra-, and infraspinatus muscles and partial encasement of the axillary vessels (►Fig. 2B). Patient underwent R0 resection of left axillary mass along with resection of axillary vein with end-to-end venous anastomosis. The axillary artery underwent a periadventitial dissection and was safeguarded (►Fig. 2C). Patient had an uneventful postoperative recovery. Histological examination revealed a malignant tumor comprising tissues derived from all three germ cell layers. Tubules lined by primitive embryonal cells as well as Homer Wright rosettes, reminiscent of immature neuroectodermal elements, were readily identified (►Fig. 2D). Mesodermal derivatives comprised islands of immature cartilage and sheets of spindle cells, while glandular structures lined by columnar cells represented the epithelial elements (►Fig. 2E, F). Other malignant germ cell elements were not identified. This was consistent with lymph node metastases from the primary palm teratoma. She received two more cycles of VeIP chemotherapy. At 12 months of follow-up, the patient is disease free.

Discussion

We report an extremely rare case of nonmidline, extragenadal, teratoma arising from the palm of a 36-year-old woman with axillary lymph node metastases. GCTs are classified as extragenadal if there is no evidence of a primary tumor in either of the gonads, testis, or ovaries. Extragenadal teratomas typically arise in midline locations, which is the track of migration of primordial germ cells that fail to complete the normal migration along the urogenital ridge to the gonadal ridges during embryonal development.⁹ This may be due to an abnormality in the primordial germ cell itself or in its microenvironment. The other theory is that germ cells transformed in the testes/ovaries undergo reverse migration. Some researchers believe that extragenadal teratomas are the result of metastases from gonadal tumors with regression of the primary.^{10,11} However, chromosomal and imprinting analysis strongly indicate the mismigrated cell theory.¹² In adults, the most common extragenadal sites of occurrence of teratoma are, in order of frequency, anterior mediastinum, abdomen, sacrococcygeal area, and pineal and suprasellar regions (central nervous system).¹³ Abdominal sites include retroperitoneum, pelvis, and retrovesical space, and are often associated with bladder or prostate. Primary GCTs of extragenadal origin comprise 3 to 5% of all GCTs.⁵

To the best of our knowledge, seven cases of nonmidline, extremity, extragenadal teratoma have been reported to date. The first reported case of extremity malignant teratoma

was in 1992 from the Tata Memorial Centre, Mumbai, Maharashtra, India, by Chinoy et al,² where the patient presented with an ulcer in the right sole of the foot. With the suspected diagnosis of squamous cell carcinoma, he underwent below knee amputation. Intraoperatively, right groin nodule was identified which on aspiration biopsy was identified to be a malignant teratoma with no evident disease in the abdomen or gonads. Later, he presented with gross disease at the groin ulcerating onto the skin, was offered systemic therapy but the patient defaulted and later died of secondary infection and septicemia. Final histopathology of the specimen turned out to be a malignant teratoma from the sole of the foot. Tumor markers were normal in this case. Second report is in 2000 where Vazquez et al³ reported a case of intraosseous teratoma in a 4-year-old girl who presented with a hip (iliac bone) mass. She also had a history of immature teratoma of the neck which was resected on day 6 of life. The neck teratoma recurred twice, at 16 months and 3.5 years of age and later in iliac bone and it appeared progressively more mature in recurrences. At the time of bone teratoma there was no evidence of neck or other metastatic sites. Similar one in proximal humerus was reported by Koh et al⁴ with no evidence of regional or distant disease and was managed by surgical resection alone. The above reported cases have been summarized in ►Table 1. Ait Benali et al⁵ described a 37-year-old man who presented with teratoma in the right arm along with multiple axillary lymph node metastasis. Gonadal examination and CECT imaging did not reveal any abnormalities and he received four courses of BEP chemotherapy. The disease remained stable and underwent wide excision with axillary dissection. Two further cycles of chemotherapy were added using the same protocol and the patient was disease free at 18 months of follow-up. Zuquello et al⁶ described an immature teratoma arising from the thigh of a 27-year-old man which was treated with wide excision followed by administration of chemotherapy. Coli et al⁷ described an immature teratoma arising from the left posteroinferior thigh of an 86-year-old lady in the absence of clinical and radiological evidence of ovarian or any other tumor which was also managed by upfront surgical resection. Another case of immature teratoma in the palm similar to ours was described by Rajpoot et al,⁸ where a diagnostic biopsy was done which revealed characteristic histopathological features and the patient was referred elsewhere with no follow-up details available. All reported presentations were in extremity with or without regional nodal involvement without the presence of an evident disease in the gonads.

In cases of soft tissue tumor, before arriving at a conclusion of soft tissue primary, metastases from other sites need to be excluded especially in poorly differentiated histology as soft tissue metastases are common for many malignancies like lung, cutaneous malignancies, etc.¹⁴ Hence, a trucut biopsy and pathological diagnosis followed by tumor marker analysis is mandatory. The pathological evaluation clinched the diagnosis in our case which showed histopathological features of an immature teratoma with presence of tissues arising from all three germ layers and the peculiar IHC

marker for epithelial components (AE1/AE2), mesenchymal components, and endodermal counterparts. In our case, the patient presented with a left palm swelling who had diagnostic biopsy elsewhere and underwent wide excision for progression at our place following three cycles of chemotherapy (BEP) and received adjuvant two cycles of chemotherapy and was under observation thereafter. Later, she presented with axillary recurrence 8 months later.

Complete surgical resection becomes the mainstay of management for extremity teratoma as otherwise it may spread regionally or distally. There is a described entity known as growing teratoma syndrome¹⁵ which is characterized by the development of enlarging teratoma masses in the retroperitoneum occurring during or after chemotherapy. It occurs due to the conversion of immature gonadal GCT to a mature form, along with increase in size of the lesions. It is more common in testicular malignancies and is believed to be secondary to chemotherapy. These lesions are often refractory to further chemotherapy and surgical resection can be curative. Hence, awareness of this entity is essential in preventing administration of excessive chemotherapy and to adopt to surgical curative options in a timely manner. Prognosis in this situation is excellent if surgical resection is complete.¹⁶ In our case, the axillary mass was proven to be an immature teratoma which showed stable disease morphologically despite decrease in SUV on PET. An R0 resection was curative. The major limitation of this study is the rarity of the presentation and hence the management options are derived from that which is used for teratoma at abdominal sites. Since teratoma is a type of GCT that does not usually respond to systemic therapy, complete surgical resection remains the mainstay of treatment. Systemic therapy may be considered in situations where the critical structures are involved but at one point it has to be followed by surgical resection. Once R0 resection has been attained, then the patient has to be kept under follow-up with clinical examination and imaging as and when required to identify any recurrences.

Conclusion

Nonmidline extragonadal GCT can present in extremity. Histopathological evaluation is diagnostic. Surgery is the curative treatment option with neoadjuvant or adjuvant chemotherapy. Nodal basins should be monitored or prophylactically addressed.

Ethics Committee Approval

None.

Patient Consent

Written informed consent has been taken and is enclosed.

Funding

None.

Conflict of Interest

None declared.

Acknowledgments

None.

References

- Ronchi A, Cozzolino I, Montella M, et al. Extragonadal germ cell tumors: not just a matter of location. A review about clinical, molecular and pathological features. *Cancer Med* 2019;8(16): 6832–6840
- Chinoy RF, Soman CS, Swaroop D, Badwar RA. Extragonadal malignant teratoma of the foot. *Indian J Cancer* 1992;29(02):96–99
- Vazquez JL, Jaramillo D, Gebhardt MC, Perez-Atayde AR. Intraosseous teratoma of the iliac bone. *Pediatr Radiol* 2000;30(04):258–261
- Koh JS, Park JH, Kang CH. A primary extragonadal teratoma of the proximal humerus. *J Korean Med Sci* 2009;24(05):989–991
- Ait Benali H, Lalya L, Allaoui M, et al. Extragonadal mixed germ cell tumor of the right arm: description of the first case in the literature. *World J Surg Oncol* 2012;10(01):69
- Zuquello RÁ, Tagliari G, Bagatini R, et al. Immature teratoma presenting as a soft-tissue mass with no evidence of other sites of involvement: a case report. *Diagn Pathol* 2016;11(01):76
- Coli A, Careri S, Gessi M, Maccauro G. Primary immature teratoma of the thigh. *Pathology* 2019;51(07):755–756
- Rajpoot J, Zaheer S, Sugandha S, Ranga S. Immature teratoma of the palm: a rare site of presentation. *Cureus* 2020;12(09):e10738
- Ueno T, Tanaka YO, Nagata M, et al. Spectrum of germ cell tumors: from head to toe. *Radiographics* 2004;24(02):387–404
- Balzer BL, Ulbright TM. Spontaneous regression of testicular germ cell tumors: an analysis of 42 cases. *Am J Surg Pathol* 2006;30(07): 858–865
- Comiter CV, Renshaw AA, Benson CB, Loughlin KR. Burned-out primary testicular cancer: sonographic and pathological characteristics. *J Urol* 1996;156(01):85–88
- Schneider DT, Schuster AE, Fritsch MK, et al. Multipoint imprinting analysis indicates a common precursor cell for gonadal and nongonadal pediatric germ cell tumors. *Cancer Res* 2001;61(19): 7268–7276
- Scully RE. Classification of human ovarian tumors. *Environ Health Perspect* 1987;73:15–25
- Plaza JA, Perez-Montiel D, Mayerson J, Morrison C, Suster S. Metastases to soft tissue: a review of 118 cases over a 30-year period. *Cancer* 2008;112(01):193–203
- Panda A, Kandasamy D, Sh C, Jana M. Growing teratoma syndrome of ovary: avoiding a misdiagnosis of tumour recurrence. *J Clin Diagn Res* 2014;8(01):197–198
- Scavuzzo A, Santana Ríos ZA, Noverón NR, Jimenez Ríos MA. Growing teratoma syndrome. *Case Rep Urol* 2014;2014:139425