



A Prospective Study to Evaluate the Prevalence of Microsatellite Instability in Endometrial Carcinoma by using Immunohistochemistry for Mismatch Repair Proteins as a Surrogate Marker

Prithviraj K. Solanki¹ Mahesh Mandolkar¹ Padmaj Kulkarni²

¹ Department of Pathology, Deenanath Mangeshkar Hospital and Research Centre, Pune

² Department of Medical Oncology, Deenanath Mangeshkar Hospital and Research Centre, Pune

Address for correspondence Prithviraj K. Solanki, DNB Pathology, Deenanath Mangeshkar Hospital and Research Centre, Pune, Maharashtra 411004, India (e-mail: drprithvirajsolanki@gmail.com).

Ind J Med Paediatr Oncol

Abstract

Aim Use of immunohistochemistry for mismatch repair (MMR) proteins to identify the prevalence of microsatellite instability (MSI) in cases of endometrial carcinoma and its subsequent correlation with various histopathological parameters.

Materials and Methods The expression of MMR proteins, viz PMS2, MLH1, MSH2, and MSH6, were assessed in 114 endometrial cancer cases by immunohistochemistry using Dako EnVision FLEX system, on paraffin blocks of tumor tissue fixed in 10% formalin.

Results We studied 114 endometrial cases for MMR protein expression, of which the majority were of endometrioid histologic subtype ($n=93$, 81.6%), whereas the remainder comprised serous carcinoma ($n=12$, 10.5%), clear cell carcinoma ($n=1$, 0.9%), carcinosarcoma ($n=5$, 4.4%), and dedifferentiated uterine carcinoma ($n=3$, 2.6%). Twenty-one (18%) of these cases were found to be deficient for MMR proteins, of which 20 were of endometrioid histologic subtype and only 1 was dedifferentiated uterine carcinoma. Loss of MMR protein expression occurred in pairs of either PMS2 and MLH1 or MSH2 and MSH6.

Conclusion MSI is one of the major molecular pathways contributing to tumorigenesis in endometrial carcinomas. Immunohistochemistry for MMR proteins is a highly sensitive and cost-effective alternative for molecular testing for MSI. It is also a great tool for screening patients for Lynch syndrome. Immunohistochemical testing for MMR should be offered to all patients of endometrial cancers.

Keywords

- ▶ mismatch repair proteins
- ▶ microsatellite instability
- ▶ Lynch syndrome
- ▶ endometrial cancer
- ▶ uterine corpus cancer

Introduction

With 417,367 (2.2% of all cancer cases) new cases diagnosed globally in 2020 and 97,370 recorded deaths, endometrial cancer is the sixth most common cancer in women.¹ In India,

endometrioid cancer is the 22nd most commonly detected malignancy, with approximately 16,413 new cases (1.2%) reported in 2020, according to Globocan data.² It is among the five most common malignancies detected in females in the Indian population.³

DOI <https://doi.org/10.1055/s-0043-1775853>.
ISSN 0971-5851.

© 2023. The Author(s).

This is an open access article published by Thieme under the terms of the Creative Commons Attribution License, permitting unrestricted use, distribution, and reproduction so long as the original work is properly cited. (<https://creativecommons.org/licenses/by/4.0/>)

Thieme Medical and Scientific Publishers Pvt. Ltd., A-12, 2nd Floor, Sector 2, Noida-201301 UP, India

According to the World Health Organization classification, endometrial carcinomas can be histologically classified as endometrioid carcinoma, serous carcinoma, clear cell carcinoma, undifferentiated and dedifferentiated carcinomas, carcinosarcomas, and others.⁴ Recent advancements in our understanding of the molecular biology of tumor cells have led to the advocacy for the inclusion of molecular characteristics in both the classification and risk stratification of Endometrial Carcinoma (EC). This is because molecular characteristics can provide a more accurate understanding of the biological behavior of a patient's disease, which can lead to improved treatment decisions. In a seminal paper published by The Cancer Genome Atlas (TCGA) in 2013, it classified endometrial cancers into four major genomic subtypes: (1) POLE (DNA polymerase ϵ) ultramutated, (2) hypermutated/microsatellite unstable (microsatellite instability [MSI]), (3) copy number low/microsatellite stable group, and (4) copy number high (serous-like) group.⁵

Numerous genes linked to cancer have been examined in endometrial carcinoma, of which the molecular phenotype known as MSI has drawn a lot of focus. Endometrial cancer is the most common cancer known to be associated with MSI after colorectal cancer.⁶ MSI is the accumulation of mismatches, insertions, and deletions in repeated nucleotide sequences due to defects in DNA mismatch repair (MMR). MMR is a crucial cellular defense system that rectifies any DNA alterations produced during DNA replication. MSI is the hallmark of a defective MMR system. DNA MMR system in patients that display MSI can be inactivated either by (1) germline mutations found in Lynch syndrome amounting to 2 to 3% of endometrial cancers or (2) somatic promoter hypermethylation and silencing of MLH1 observed in 20% of sporadic endometrial cancers.⁷⁻⁹ Regardless of the underlying mechanism, the inactivation of the DNA MMR system leads to an increased mutation rate, which contributes to tumorigenesis. The majority of MSI in endometrial and colorectal cancers is caused by defects in DNA MMR genes, mainly MLH1, MSH2, MSH6, and PMS2.⁹ Loss of function of MMR protein MLH1 due to methylation of the MLH1 gene promoter, seen more commonly in sporadic tumors, and thus also loss of its binding partner PMS2, can be detected as a loss of expression of these proteins by immunohistochemical (IHC).¹⁰

As per the recommendations of National Comprehensive Cancer Network, all newly diagnosed ECs patients should be tested for loss of MMR function via IHC and/or MSI analysis independent of the clinical criteria.¹¹ IHC screening for MMR proteins is a relatively affordable alternative and can guarantee sensitivity and specificity at the same time. MMR proteins exist in heterodimers viz, PMS2 dimerizes with MLH1 and MSH2 dimerizes with MSH6. This explains the concurrent loss of either PMS2 and MLH1 or MSH2 and MSH6 in ECs.¹²

The tumors with MSI have a high incidence of somatic mutations that results in the production of proteins with new immunogenicity. The host immune system responds to these new antigens by excessive peritumoral T-cell infiltration.¹³ Cancer cells circumvent the host immunological response by activating pathways that inhibit T-cell activation

(cytotoxic T-lymphocyte-associated antigen and programmed cell death ligand 1).¹⁴ This principle forms the basis for the use of immune checkpoint inhibitors as potential therapeutic agents in tumors with MSI. A phase 2 study was conducted by Le et al to evaluate the clinical activity of the anti-PD 1 drug, pembrolizumab, in tumors with MMR that included colorectal as well as noncolorectal tumors demonstrated the importance of MMR status in predicting the clinical benefit of immune checkpoint blockade with pembrolizumab.¹⁵

Dostarlimab, an anti-PD 1 drug, was used singularly by Cercek et al to treat MMR-deficient (dMMR), locally progressed rectal cancer. They observed that this tumor was extremely sensitive to PD 1 inhibition.¹⁶ Thus, MSI analysis is also a predictive biomarker for the therapeutic efficacy of anti-PD ligand antibodies.¹³ According to the College of American Pathologists guidelines for MMR and MSI testing, which were recently endorsed by the American Society of Clinical Oncology, immunohistochemistry for MMR proteins is preferred over MSI testing by polymerase chain reaction or next-generation sequencing for the identification of DNA MMR defects in patients with endometrial cancer who are being considered for immune checkpoint inhibitors.¹⁷

In this study, we evaluated the endometrial cancers for their expression of MMR proteins by IHC and correlated their MMR status with age and various histopathological parameters.

Materials and Methods

This study was conducted in a tertiary hospital in western part of India between June 2018 and June 2020 to survey the prevalence of MMR protein deficiency using immunohistochemistry in the hysterectomy specimens of endometrial cancers. The patient data were obtained from the electronic database of the hospital records as well as the departmental register of histopathological specimens received in the lab. This study included only the cases for which a complete assessment of pathological parameters and staging was available. In addition, cases that had received presurgical neoadjuvant therapy were excluded from this study

Immunohistochemistry testing for the four MMR proteins: MSH2 (clone FE11), MSH6 (clone EP49), PMS2 (clone EP51), and MLH1 (clone ES05) was done on 114 endometrial cancer cases. Testing was done on the endometrial cancer tumor tissue paraffin blocks of hysterectomy specimens using the Dako EnVision FLEX system. The complete absence of nuclear staining with a positive internal control was considered a loss of nuclear expression of an MMR protein. Tumor with loss of nuclear expression of any MMR protein was regarded as dMMR; tumor cells with intact nuclear expression of all four MMR proteins were regarded as MMR-proficient (**► Fig. 1**).

The sample size was calculated using formula: $n = p(1 - p) [(z_{\alpha} + z_{1 - \beta}) / (p - p_0)]^2$, where n is the sample size, $p = 0.52$ (52% prevalence of MSI-H in endometrial cancer patients), α is Type I error = 5%; $z_{\alpha} = 1.96$ two-sided, $z_{\alpha} = 1.64$ one-sided, β is Type II error, $1 - \beta$ is power; $z_{1 - \beta} = 0.84$ for $1 - \beta = 80\%$, effect size = $(p - p_0) = \pm 0.13$ (13%).

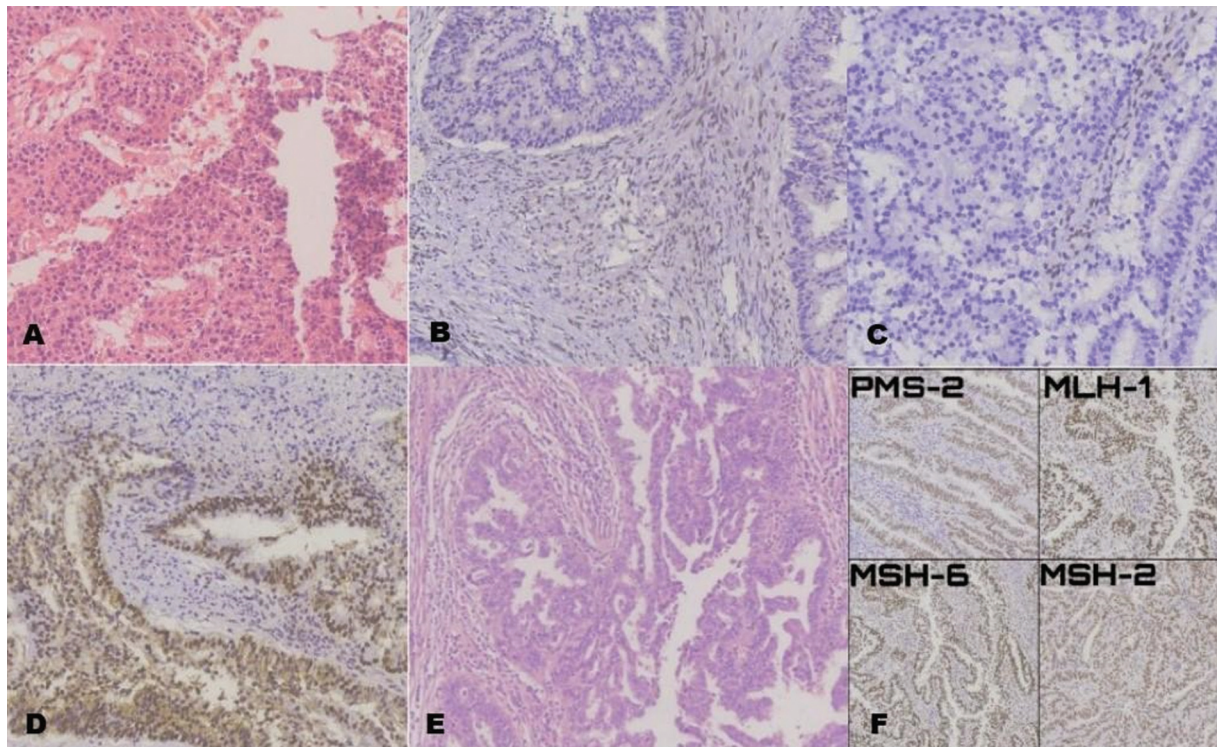


Fig. 1 H&E image of endometrioid carcinoma, FIGO grade 2 (A) with corresponding IHC for MMR proteins: There is loss of PMS2 (B) and MLH1 (C) in the tumor nuclei and intact expression of MSH2 /MSH6 (D). H&E image of serous carcinoma with corresponding intact nuclear MMR protein expression by IHC (F). FIGO, International Federation of Gynecology and Obstetrics; H&E, hematoxylin and eosin; IHC, immunohistochemical; MMR, mismatch repair.

Statistical Package for the Social Sciences (SPSS Inc. 233, Chicago, Illinois, United States) software was used for statistical analysis. Unpaired Student's *t*-test was used for quantitative data and a χ^2 test was used for categorical variables with more than two; *p*-values from Fisher's exact test are presented where appropriate due to small counts.

This study was reviewed and approved by the Institutional Ethical Committee at the meeting held on December 28, 2018 (Number: DNB_2018_PATH_005) and adhered to the tenets of the Declaration of Helsinki. The patient's consent was waived by the Institutional Committee.

Results

The findings of our study, which analyzed 114 endometrial cancer specimens for expression of MMR proteins and its relationship to various histopathological parameters and age, are summarized in ►Table 1. The average age of the study population was 62 years (range: 36–91 years). Among these, 9 patients were less than or equal to 50 years of age at the time of diagnosis, whereas the rest were more than 50 years old. A strong correlation was found between dMMR and age greater than 50 years ($p = 0.016$). On histologic subtyping, endometrioid carcinoma accounted for the majority of cases (93 cases, 81.6%). These tumors were graded as per the International Federation of Gynecology and Obstetrics (FIGO) criteria. Nonendometrioid carcinomas, except for mucinous carcinomas, are conventionally considered high grade. Out of the 93 endometrioid cancer

cases found, 69 were Grade 1, 16 were Grade 2, and 8 were Grade 3.

On IHC analysis for MMR proteins, it was found that 21 out of 114 cases (18.4%) of endometrial cancers were deficient for MMR proteins (95% confidence interval [CI], 11.3–25.5%).

Twenty cases had a combined loss of PMS2 and MLH1, whereas only one case had a combined loss of MSH2 and MSH6. Tumors with a loss of only one MMR protein were not present in our study. Furthermore, the histologic subtypes of endometrioid cancer ($n = 20$) and dedifferentiated uterine carcinoma ($n = 1$) accounted for all the dMMR cases. The prevalence of MMR deficiency in endometrioid carcinomas was 21.3%, with a 95% CI of 13.8 to 28.8%.

Eighty-five cases of low FIGO grade (Grades 1 and 2) endometrioid carcinoma made up our study, whereas 29 cases were high grade, which combined both endometrioid ($n = 10$) and nonendometrioid carcinoma ($n = 19$). A total of 16 low-grade and 5 high-grade cases with deficient MMR expression were identified.

Tumor invasion into greater than or equal to half the myometrium was identified in 56 cases, of which 8 cases showed deficient MMR expression. Tumors having less than half or absence of invasion comprised 45 cases, of which 13 cases showed deficient MMR expression. We could not establish any statistically significant relation between myometrial invasion and MMR expression.

Subsequently, as per FIGO staging classification, 43% of the cases were stage group IA (pT1a), 30.7% were stage IB (pT1b), 13.2% cases were stage group II (pT2), 4.4% were stage IIIA

Table 1 Comparison between different parameters and expression of mismatch repair proteins

Number of cases (%)	Retained expression of all markers	Loss of MLH1/PMS2 expression	Loss of MSH2/MSH6 expression	Total	p-Value
Histology diagnosis					
Endometrioid carcinoma	73 (78.5%)	19 (20.43%)	1 (1.07%)	93	
Serous carcinoma	12 (100%)	0	0	12	0.737
Clear cell carcinoma	1 (100%)	0	0	1	
MMMT	5 (100%)	0	0	5	
DDUC	2 (66.67%)	1 (33.33%)	0	3	
FIGO stage					
IA	38 (77.55%)	11 (22.45%)	0	49	0.094
IB	31 (88.57%)	4 (11.43%)	0	35	
II	13 (86.67%)	2 (13.33%)	0	15	
IIIA	5 (100%)	0	0	5	
IIIB	1 (50%)	1 (50%)	0	2	
IIIC1	2 (50%)	2 (50%)	1	5	
IVB	3 (100%)	0	0	3	
Grade					
G1	58 (84.06%)	11 (15.94%)	0	69	
G2	11 (68.75%)	4 (25%)	1 (6.25%)	16	0.071
G3	6 (60%)	4 (40%)	0	10	
High	18 (94.73%)	1 (5.27%)	0	19	
Myometrial invasion					
< 1/2 or absent	45 (77.58%)	12 (20.69%)	1 (1.72%)	58	0.388
≥1/2	48 (85.71%)	8 (14.28%)	0	56	
Age (y)					
≤50	9 (69.23%)	3 (23.07%)	1 (7.7%)	13	0.016
> 50	84 (83.17%)	17 (16.83%)	0	101	

Abbreviations: DDUC, dedifferentiated uterine carcinoma; FIGO, International Federation of Gynecology and Obstetrics; MMT, malignant mixed müllerian tumor (carcinosarcoma).

(pT3a), 1.8% were stage IIIB (pT3b), and 2.6% cases were stage group IVB (pM1). Only four of the 21 patients with deficient MMR expression were stage III or higher at the time of diagnosis. We did not find any statistically significant association between dMMR protein expression and tumor stage group, myometrial invasion, histologic grade, or morphological subtype.

Discussion

The MSI phenotype continues to serve as the hallmark of defective MMR. This is because germline mutations in MLH1, MSH2, MSH6, and PMS2 are responsible for genetic susceptibility to colorectal cancer known as Lynch syndrome or hereditary nonpolyposis colorectal cancer.¹⁸

The role of MSI as a marker for favorable prognosis has been very well established in colorectal cancers. However, its role in endometrial cancers is yet to be ascertained. A meta-analysis done by Raffone et al found that MSI is an unfavorable prognostic factor in early-stage EC, which otherwise has

a good prognosis. Paradoxically, MSI is an advantageous prognostic factor in high-risk carcinomas, which typically have a poor prognosis.¹⁹

In our study, the prevalence of MMR proteins deficiency was found in 18% (21 out of 114) cases of endometrial cancers. Twenty cases showed a concurrent loss of PMS2 and MLH1, whereas only one case showed a concurrent loss of MSH2 and MSH6. The prevalence of MMR deficiency ranged from 15 to 30% in various other studies.^{19–22} The majority of our cases (20 out of 21) with deficient MMR proteins were of endometrioid carcinoma (20 cases) on histologic subtyping, of which 19 cases were deficient for PMS2 and MLH1, whereas only 1 case showed deficient expression of MSH2 and MSH6. A single case of dedifferentiated carcinoma was deficient for MMR proteins. Other studies conducted showed a statistically significant association between MMR deficiency and endometrioid and dedifferentiated/undifferentiated uterine carcinomas.^{20,21,23} Although we had similar observations, we could not establish statistically significant conclusions ($p = 0.737$) as the number of nonendometrioid cancers was less. We found no association

between the grade of tumor and MMR status, which is similar to other studies.^{19–21} We were unable to establish any statistically significant association between myometrial invasion and MMR deficiency, which has been reported in a few studies.^{20,21} This difference in results could be due to a small sample size.

A comprehensive review and meta-analysis by Raffone et al examined the diagnostic precision of MMR proteins IHC as a stand-in for molecular testing for MSI in endometrial malignancies, as well as the possibility of using a panel of just two MMR proteins to further reduce costs. They found IHC for MMR proteins to be a highly reliable substitute for MSI molecular testing (sensitivity of 0.96 and specificity of 0.95) in endometrial cancer. They further proposed that the combination of MSH6 and PMS2 may help to reduce costs while maintaining diagnostic accuracy.¹⁹

Talhouk et al designed a molecular categorization system—Proactive Molecular Risk Classifier for Endometrial Cancer—based on the TCGA molecular subcategories and tested its practicality and prognostic potential in ECs using immunohistochemistry for the MMR and P53 proteins and POLE sequencing. Four prognostic subgroups were identified: dMMR, POLE, p53 Wild Type (wt), and p53 Null/Missense Mutations (abn), each of which had unique overall, disease-specific, and progression-free survival rates. The most promising outcome was seen in tumors with POLE exonuclease domain mutations, and the worst prognosis was seen in tumors with p53 abn.²⁴ Such studies are required in the Indian population to assess biological behavior and to improve clinical management and outcomes. The advantages of IHC for MMR include its simplicity, availability, and relatively lower cost compared with molecular testing. Patterns of loss of MMR proteins can further help in guiding the reflex molecular testing for MSI.¹⁹

The disadvantages of IHC for MMR proteins include inter-observer variation in interpretation especially in cases with heterogeneous staining patterns and false negativity (production of nonfunctional protein which stains with MMR IHC).^{19,25}

Limitations

Clinical follow-up of the patients and its correlation with MSI status was not assessed.

Recommendations

A larger study with longer follow-up will help to confirm the relationship between the histology of endometrial carcinomas and MSI status.

Conclusion

MSI is one of the major molecular pathways contributing to tumorigenesis in endometrial carcinomas. Immunohistochemistry for MMR proteins is a highly sensitive and cost-effective alternative for molecular testing for MSI. It is also a tool for screening patients for Lynch syndrome. IHC testing for MMR should be offered to all patients of endometrial cancers.

Author's Contributions

This article has been read and approved by all the authors.

Funding

None.

Conflict of Interest

None declared.

Acknowledgments

The authors would like to specially acknowledge Dr. Deepa Puntambekar for the initial conceptualization, Dr. Asawari Kanade for statistical analysis, and Sucheta Nir-mal, Meenal Khire, Sushma Ingale, Snehal Marne, and Shivaji Darekar for technical assistance.

References

- Sung H, Ferlay J, Siegel RL, et al. Global Cancer Statistics 2020: GLOBOCAN estimates of incidence and mortality worldwide for 36 cancers in 185 countries. *CA Cancer J Clin* 2021;71(03):209–249
- https://gco.iarc.fr/today/online-analysis-table?v=2020&mode=cancer&mode_population=continents&population=900&populations=356&key=asr&sex=2&cancer=39&type=0&statistic=5&prevalence=0&population_group=0&ages_group%5B%5D=0&ages_group%5B%5D=17&group_cancer=1&include_nmssc=0&include_nmssc_other=1#collapse-by_country
- Mathur P, Sathishkumar K, Chaturvedi M, et al; ICMR-NCDIR-NCRP Investigator Group. Cancer Statistics, 2020: report from National Cancer Registry Programme, India. *JCO Glob Oncol* 2020; 6:1063–1075
- International Agency for Research on Cancer, World Health Organization. WHO Classification of Female Genital Tumors: Who Classification of Tumors. 5th ed. (WHO Classification of Tumors Editorial Board, ed.). IARC; 2020
- Kandoth C, Schultz N, Cherniack AD, et al; Cancer Genome Atlas Research Network. Integrated genomic characterization of endometrial carcinoma. *Nature* 2013;497(7447):67–73[published correction appears in *Nature*. 2013;500(7461):242]
- Win AK, Lindor NM, Young JP, et al. Risks of primary extracolonic cancers following colorectal cancer in lynch syndrome. *J Natl Cancer Inst* 2012;104(18):1363–1372
- Buecher B, De Pauw A, Bazire L, et al. Sporadic endometrial adenocarcinoma with MMR deficiency due to biallelic MSH2 somatic mutations. *Fam Cancer* 2018;17(02):281–285
- Kahn RM, Gordhandas S, Maddy BP, et al. Universal endometrial cancer tumor typing: how much has immunohistochemistry, microsatellite instability, and MLH1 methylation improved the diagnosis of Lynch syndrome across the population? *Cancer* 2019; 125(18):3172–3183
- Kurman RJ, Ellenson LH, Ronnett BM. *Blaustein's Pathology of the Female Genital Tract*. Springer; 2011
- Ligtenberg MJ, Kuiper RP, Chan TL, et al. Heritable somatic methylation and inactivation of MSH2 in families with Lynch syndrome due to deletion of the 3' exons of TACSTD1. *Nat Genet* 2009;41(01):112–117
- Nccn.org. Accessed June 26, 2022 at: https://www.nccn.org/professionals/physician_gls/pdf/uterine_blocks.pdf
- Mojtahed A, Schrijver I, Ford JM, Longacre TA, Pai RK. A two-antibody mismatch repair protein immunohistochemistry screening approach for colorectal carcinomas, skin sebaceous tumors, and gynecologic tract carcinomas. *Mod Pathol* 2011;24(07):1004–1014

- 13 Kunitomi H, Banno K, Yanokura M, et al. New use of microsatellite instability analysis in endometrial cancer. *Oncol Lett* 2017;14(03):3297–3301
- 14 Kumar V, Abbas AK, Aster J. *Robbins & Cotran Pathologic Basis of Disease E-Book*. 10th ed. Elsevier; 2020
- 15 Le DT, Uram JN, Wang H, et al. PD-1 blockade in tumors with mismatch-repair deficiency. *N Engl J Med* 2015;372(26):2509–2520
- 16 Cercek A, Lumish M, Sinopoli J, et al. PD-1 blockade in mismatch repair-deficient, locally advanced rectal cancer. *N Engl J Med* 2022;386(25):2363–2376
- 17 Vikas P, Messersmith H, Compton C, et al. Mismatch repair and microsatellite instability testing for immune checkpoint inhibitor therapy: ASCO endorsement of College of American Pathologists guideline. *J Clin Oncol* 2023;41(10):1943–1948
- 18 Hendriks YM, de Jong AE, Morreau H, et al. Diagnostic approach and management of Lynch syndrome (hereditary nonpolyposis colorectal carcinoma): a guide for clinicians. *CA Cancer J Clin* 2006;56(04):213–225
- 19 Raffone A, Travaglino A, Cerbone M, et al. Diagnostic accuracy of immunohistochemistry for mismatch repair proteins as surrogate of microsatellite instability molecular testing in endometrial cancer. *Pathol Oncol Res* 2020;26(03):1417–1427
- 20 Black D, Soslow RA, Levine DA, et al. Clinicopathologic significance of defective DNA mismatch repair in endometrial carcinoma. *J Clin Oncol* 2006;24(11):1745–1753
- 21 Kanopienė D, Smailytė G, Vidugirienė J, Bacher J. Impact of microsatellite instability on survival of endometrial cancer patients. *Medicina (Kaunas)* 2014;50(04):216–221
- 22 Basil JB, Goodfellow PJ, Rader JS, Mutch DG, Herzog TJ. Clinical significance of microsatellite instability in endometrial carcinoma. *Cancer* 2000;89(08):1758–1764
- 23 Broaddus RR, Lynch HT, Chen LM, et al. Pathologic features of endometrial carcinoma associated with HNPCC: a comparison with sporadic endometrial carcinoma. *Cancer* 2006;106(01):87–94
- 24 Talhouk A, McConechy MK, Leung S, et al. Confirmation of ProMisE: a simple, genomics-based clinical classifier for endometrial cancer. *Cancer* 2017;123(05):802–813
- 25 Bruegl AS, Ring KL, Daniels M, Fellman BM, Urbauer DL, Broaddus RR. Clinical challenges associated with universal screening for Lynch syndrome-associated endometrial cancer. *Cancer Prev Res (Phila)* 2017;10(02):108–115