



# Clinical Syndrome of Seizures, Headache, and Visual Blurring in Metastatic Carcinoma Colon

Lakshmi Raj<sup>1</sup> T.M. Anoop<sup>1</sup>  Rakesh CA<sup>2</sup>

<sup>1</sup>Department of Medical Oncology, Regional Cancer Centre, Thiruvananthapuram, Kerala, India

<sup>2</sup>Department of Radiodiagnosis, Regional Cancer Centre, Thiruvananthapuram, Kerala, India

Address for correspondence T.M. Anoop, MD, DM, DNB, FRCP (Edin), Associate Professor, Department of Medical Oncology, Regional Cancer Centre, Thiruvananthapuram, Kerala, 596011, India (e-mail: dranooptm@yahoo.co.in).

Ind J Med Paediatr Oncol 2024;45:64–65.

## Abstract

### Keywords

- ▶ bevacizumab
- ▶ medical oncology
- ▶ posterior reversible encephalopathy syndrome (PRES)
- ▶ magnetic resonance imaging

A 51-year-old lady diagnosed as a case of metastatic carcinoma colon stage IV involving lung and left adrenal metastasis was initiated with palliative chemotherapy with FOLFOX-6 chemotherapy infusion regimen that consisted of 5-fluorouracil, calcium leucovorin, and oxaliplatin and injection bevacizumab was added to cycle seven of FOLFOX-6 chemotherapy. After 2 months of initiating bevacizumab, she was presented with one episode of generalized tonic clonic seizure, headache, and visual blurring of 2 days duration and magnetic resonance imaging brain T2 fluid-attenuated inversion recovery image revealed subcortical white matter edema in bilateral frontoparietal, occipital, left temporal lobes (Fig. 1A and B), and hyperintense edema with effacement of folia in both cerebellum with nodular areas of contrast enhancement suggestive of posterior reversible encephalopathy syndrome.

The clinical syndrome of posterior reversible encephalopathy syndrome (PRES) is characterized by varied clinical symptomatology like headache, altered consciousness, visual disturbances, and seizures. Sometimes neurological features such as aphasia and sensory changes are also seen.<sup>1</sup> Pathophysiology of PRES is attributed to autoregulatory failure and hypertension. This results in brain hyperperfusion, especially in arterial border zones that may lead to breakdown of the blood–brain barrier allowing extravasation of fluid and blood products into brain parenchyma. The incidence of chemotherapy-associated PRES is increasing nowadays. The platinum-containing regimens, Cyclophosphamide, Doxorubicin, Vincristine and Prednisone (CHOP) regimen and gemcitabine, have been implicated in the causation of PRES.

A 51-year-old lady diagnosed as a case of carcinoma colon stage IV involving lung and left adrenal metastasis was initiated with palliative chemotherapy with FOLFOX-6 chemotherapy infusion regimen that consisted of 5-fluorouracil, calcium leucovorin, and oxaliplatin. Response assessment using com-

puted tomographic chest abdomen and pelvis, following six cycles of chemotherapy, showed stable residual ascending colonic eccentric wall thickening up to 2.1 cm for a length of 3 cm and stable three pulmonary nodule in right lower, middle lobe, and lingular segment. She completed 12 cycles of FOLFOX-6 chemotherapy. Injection bevacizumab was added to cycle seven of FOLFOX-6 chemotherapy. The reason for adding bevacizumab toward 7th cycle was due to financial difficulty at the time of initiation of treatment. There was no prior history of hypertension, underlying kidney disease, and autoimmune disease. Her blood pressure was 130/80 mm Hg at presentation, before initiation of bevacizumab and during the course of bevacizumab. After 2 months of initiating bevacizumab, she was presented with one episode of generalized tonic-clonic seizure, headache, and visual blurring of 2 days duration. She had no history of new medications, trauma to head, or infection prodrome. On examination, patient was drowsy, vitals were stable, and central nervous system (CNS) examination showed no focal neurological deficits or no neck stiffness.

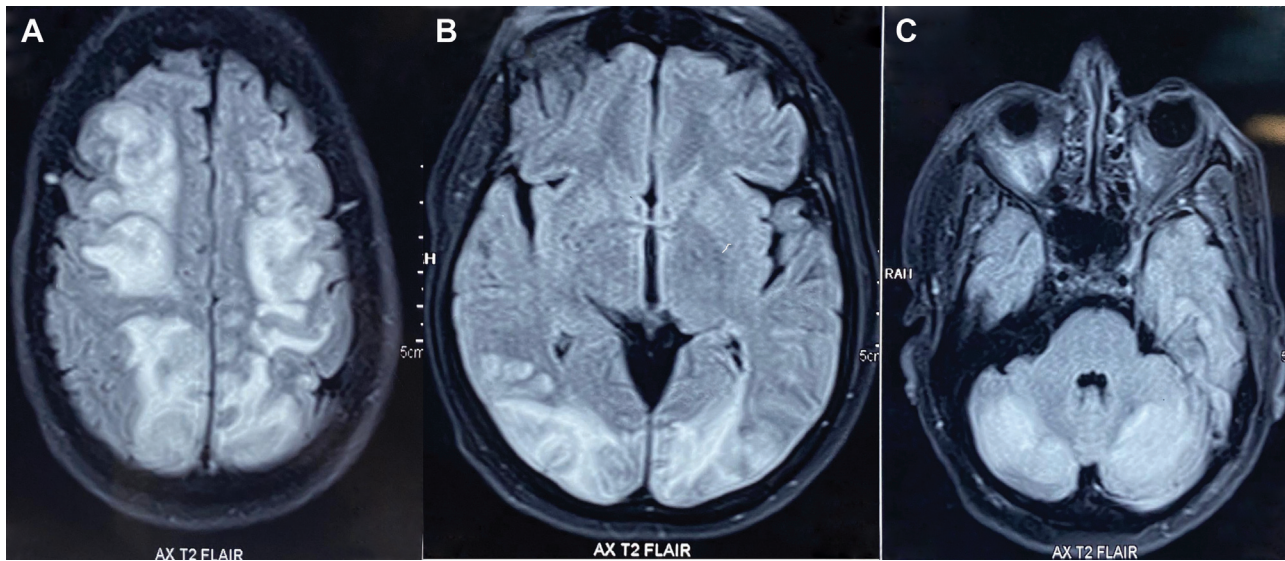
article published online  
September 22, 2023

DOI <https://doi.org/10.1055/s-0043-1772710>.  
ISSN 0971-5851.

© 2023. The Author(s).

This is an open access article published by Thieme under the terms of the Creative Commons Attribution License, permitting unrestricted use, distribution, and reproduction so long as the original work is properly cited. (<https://creativecommons.org/licenses/by/4.0/>)

Thieme Medical and Scientific Publishers Pvt. Ltd., A-12, 2nd Floor, Sector 2, Noida-201301 UP, India



**Fig. 1** MRI Brain T2 FLAIR image showing subcortical white matter oedema in bilateral frontoparietal, occipital, left temporal lobes (A-B) and hyper-intense edema with effacement of folia in both cerebellum with nodular areas of contrast enhancement (C) suggestive of Posterior reversible encephalopathy syndrome (PRES).

Cardiovascular, respiratory, and abdominal examination was unremarkable. There was documented hypertension of blood pressure of 140/90 mm Hg but no evidence of proteinuria. Magnetic resonance imaging (MRI) brain T2 fluid-attenuated inversion recovery (FLAIR) image revealed subcortical white matter edema in bilateral frontoparietal, occipital, and left temporal lobes (→Fig. 1A and B) and hyperintense edema with effacement of folia in both cerebellum with nodular areas of contrast enhancement suggestive of PRES (→Fig. 1C). During her admission, she was given antihypertensives and anti-epileptics. She was discharged on fifth day post-admission after clinical resolution of her symptoms. She was reviewed 1 week post-discharge and she had no further episodes of seizures or other CNS symptoms. In our patient, bevacizumab is most likely the causative agent for PRES. The mechanism by which bevacizumab causes PRES is hypothesized that it disrupts the blood-brain barrier through endothelial dysregulation resulting in hyperperfusion and vasogenic edema leading to failure of autoregulation.<sup>2</sup> Bevacizumab-induced hypertension might also have contributed to PRES. The time between starting a medicine and the onset of PRES has not been well described. Typically, PRES occurs within the half-life of bevacizumab that is 20 days, but it can occur from 16 hours to 1 year.

There are various conditions that would be mistaken for PRES that could lead to diagnostic confusion. They include viral and autoimmune encephalitis, demyelinating disease, CNS vasculitis, central/extrapontine myelinolysis, and cerebral venous thrombosis. The typical MRI features include almost symmetrical hemispheric vasogenic edema affecting subcortical white matter and often extending to the overlying cortex, with FLAIR sequences. There are three patterns of postcontrast enhancement like a leptomeningeal pattern, a cortical pattern, or a combined pattern. Patients typically show symptomatic improvement within 2 weeks of symp-

tom onset. Prompt recognition of syndrome is critical since it is reversible with appropriate management.<sup>3</sup>

#### Authors' Contributions

L.R., R.C.A., and T.M.A. were involved in data collection, literature review, manuscript preparation, and final approval

#### Declaration of Patient Consent

The authors certify that they have obtained all appropriate patient consent forms. In the form, the patient has given their consent for her images and other clinical information to be reported in the journal. The patient understands that their names and initials will not be published, and due efforts will be made to conceal their identity, but anonymity cannot be guaranteed.

#### Funding

None.

#### Conflict of Interest

None declared.

#### References

- Allen JA, Adlakha A, Bergethon PR. Reversible posterior leukoencephalopathy syndrome after bevacizumab/FOLFIRI regimen for metastatic colon cancer. *Arch Neurol* 2006;63(10): 1475–1478
- Glusker P, Recht L, Lane B. Reversible posterior leukoencephalopathy syndrome and bevacizumab. *N Engl J Med* 2006;354(09): 980–982, discussion 980–982
- Hamid M, Ghani A, Micaily I, Sarwar U, Lashari B, Malik F. Posterior reversible encephalopathy syndrome (PRES) after bevacizumab therapy for metastatic colorectal cancer. *J Community Hosp Intern Med Perspect* 2018;8(03):130–133