



Isolated Cerebral Metachronous Metastasis in Fibular Osteosarcoma: A Rare Case Report with Review of Literature

Manoj Kumar Nayak¹ Sameer Rastogi² Leve Joseph Sebastian¹ Ghazal Tansir²
Anubhav Narwal³

¹ Department of Neuroimaging and Interventional Neuroradiology, All India Institute of Medical Sciences, New Delhi, India

² Department of Medical Oncology, All India Institute of Medical Sciences, New Delhi, India

³ Department of Pathology, All India Institute of Medical Sciences, New Delhi, India

Address for correspondence Leve Joseph Sebastian, DM, Department of Neuroimaging and Interventional Neuroradiology, All India Institute of Medical Sciences, New Delhi 110049, India (e-mail: leve_s@yahoo.com).

Ind J Med Paediatr Oncol

Abstract

Isolated brain involvement is rarely reported as isolated metachronous metastasis from osteosarcoma. Herein, we report a case of fibular osteosarcoma in a young female who presented with solitary hemorrhagic metachronous cerebral metastasis after years of disease-free interval. Imaging showed a large mass lesion in the right posterior temporal lobe with internal areas of bleed not associated with calcification or ossification mimicking high-grade glioma. No other sites of distant metastases were found on the workup. Two-dimensional echocardiography was done to rule out any cardiac anomaly, including the shunt defect, but no abnormality was detected. She was operated for the cerebral lesion, and histopathology of the resected specimen showed osteosarcoma. The patient was started on chemotherapy and is doing well so far. This case presents a unique scenario of osteosarcoma with an isolated lesion in the brain without any other site of distant metastasis.

Keywords

- ▶ osteosarcoma
- ▶ brain metastasis
- ▶ high-grade glioma
- ▶ lung metastasis

Introduction

Osteosarcoma is the most common primary malignant bone tumor of the long bones, usually presenting in the second decade.¹ Sixty to seventy percent of localized osteosarcoma treated with surgery and intensive chemotherapy will have 5-year event-free survival.² A 3-monthly follow-up for at least 2 years is recommended postchemotherapy, subsequently 6 monthly for the next 3 to 5 years, 6 to 12 monthly for the next 5 to 10 years, and then every 6 to 24 months according to tumor grades and genetics.³ Low-dose computed tomography (CT) protocol for the chest CT for detection of lung metastasis is recommended, as most of the patients with osteosarcoma are younger population and will have a

risk of radiation-induced second malignancy.³ Osteosarcoma recurring with isolated metastasis to the brain is relatively rare because the lungs are the most common site in approximately 90% of patients, followed by the skeleton in 50% of patients.⁴ Bindal et al demonstrated that four patients with osteosarcoma had brain metastasis without lung involvement, but there was an inadequate examination of the lungs by CT scan.⁵ Two cases of isolated brain metastasis were also seen in patients with osteosarcoma without having active lung metastasis.^{6,7} Another case of osteosarcoma described presented with isolated brain metastasis without lung involvement due to patent foramen ovale.⁸ This case raises pertinent questions regarding the management of similar

DOI <https://doi.org/10.1055/s-0043-1770904>.
ISSN 0971-5851.

© 2023. The Author(s).

This is an open access article published by Thieme under the terms of the Creative Commons Attribution License, permitting unrestricted use, distribution, and reproduction so long as the original work is properly cited. (<https://creativecommons.org/licenses/by/4.0/>)

Thieme Medical and Scientific Publishers Pvt. Ltd., A-12, 2nd Floor, Sector 2, Noida-201301 UP, India

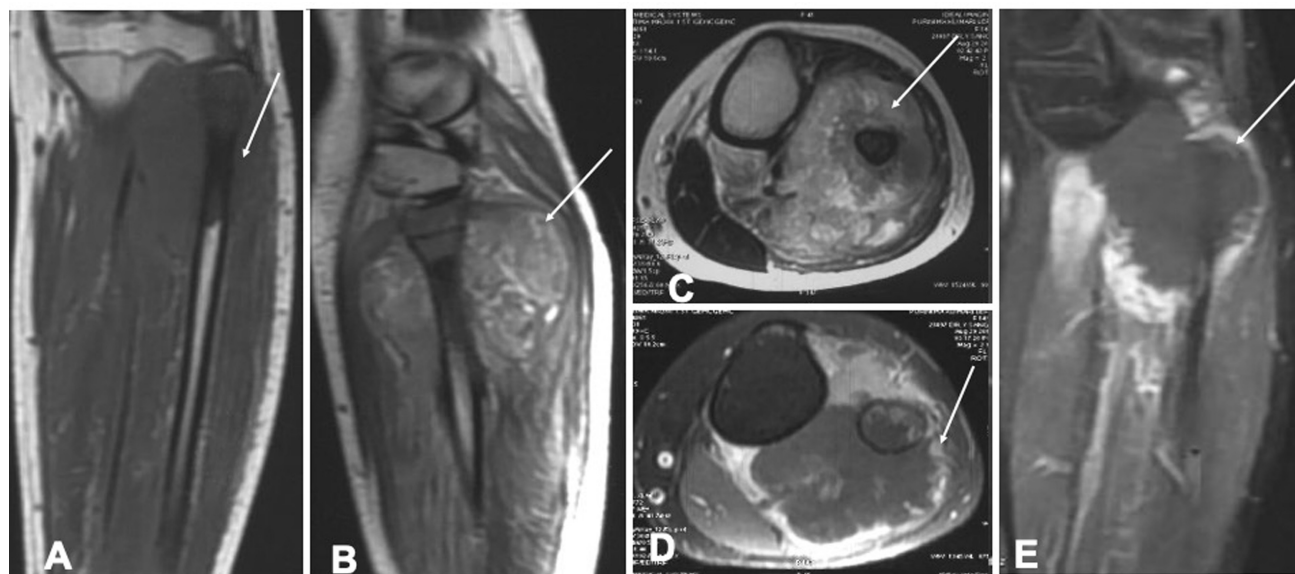

Fig. 1 Magnetic resonance imaging of the calf showing the fibular osteosarcoma. Sagittal T1 (A), sagittal T2 (B), and axial T2 (C) showed heterogeneous a heterogenous lesion involving the upper end of the fibula with adjacent soft tissue components (arrow). Axial phase-contrast (PC; D) and sagittal T1 PC (E) showed peripheral enhancement with a non-enhancing internal necrotic component (arrow).

patients because the optimal treatment in such patients is not yet well defined. We report a case of isolated brain metastasis in a patient with recurrent fibular osteosarcoma without any documented cardiac abnormality or another site of metastasis.

Case Report

A 17-year-old female initially presented with pain and swelling in the left calf for 1 month. Initial evaluation with magnetic resonance imaging (MRI) of the lower limb (**Fig. 1A–E**) showed a heterogeneous lesion in both T1-weighted and T2-weighted images at the left upper fibula with surrounding peripheral enhancing soft tissue lesion (70 × 63 × 63mm) and medullary changes that suggested the radiological possibility of osteosarcoma, Ewing's sarcoma, or chronic osteomyelitis. Histopathology findings on biopsy showed the tumor cell had hyperchromatic pleomorphic nucleoli with a high nuclear/ cytoplasm ratio and a moderate amount of cytoplasm. The tumor showed overall areas of necrosis (80–90%) with few areas of chondroblastic differentiation with features consistent with conventional osteosarcoma. CT chest was done for metastatic screening and found to be normal. The patient was started on neoadjuvant ifosfamide, doxorubicin, cisplatin protocol followed by surgery and adjuvant chemotherapy within 8 months. She had developed ifosfamide encephalopathy during chemotherapy post the eighth cycle, following which further chemotherapy was withheld. She was on regular follow-up, doing fine for the next year and CT chest was normal. The patient started having dull aching, right temporal headache after 1 year of the last cycle of chemotherapy for which she was evaluated with CT scan in a local hospital, which showed a neoplastic mass in the right cerebral hemisphere causing a mass effect with midline shift to the left side (**Fig. 2A**). MRI was

performed after 20 days of symptom onset showed a right supratentorial mass lesion in the right posterior temporal lobe with internal bleeding and peripheral enhancement, mass effect with midline shift. The lesion was T1 hypointense with focal areas of hyperintensities, T2 hyperintense with fluid–fluid level, multiple areas of blooming on susceptibility-weighted imaging, and without restriction on diffusion-weighted imaging (**Fig. 2B–E**). Elevated perfusion was seen within the lesion and irregular shaggy enhancement on the postcontrast study (**Fig. 2F, G**). No soft ossification or calcification was seen on phase images. With these constellations of findings, an imaging diagnosis was made of high-grade glioma. The second possibility was osteosarcoma metastasis, as known primary was osteosarcoma of fibula but was confounded by the absence of other metastatic areas and no calcification within the tumor mass. She was admitted to the oncology department and evaluated with positron emission tomography-computed tomography, which showed remission in the primary carcinoma site, with no other metastatic lesion anywhere in the body. Neurosurgery opinion was taken and was they advised for surgery as the tumor was quite big with radiological features suggestive of a high-grade tumor. Right frontotemporal craniotomy and gross total excision of the tumor were done. Intraoperative findings showed an intra-axial firm to hard whitish solid cystic lesion arising from the right lateral ventricle and extending to the temporal base, invading the pial surface. The tumor was dissected circumferentially in a piecemeal fashion and excised with no gross residual disease. Histopathology of the resected lesion showed a tumor in the right lateral ventricle extending to the temporal lobe comprised of multiple firm-to-hard tissue pieces measuring 9 × 8 × 1cm. Microscopy sections examined showed that the tumor was composed of spindle cells, mitosis, and areas of necrosis with lacy osteoid formation and a few chondroblastic areas

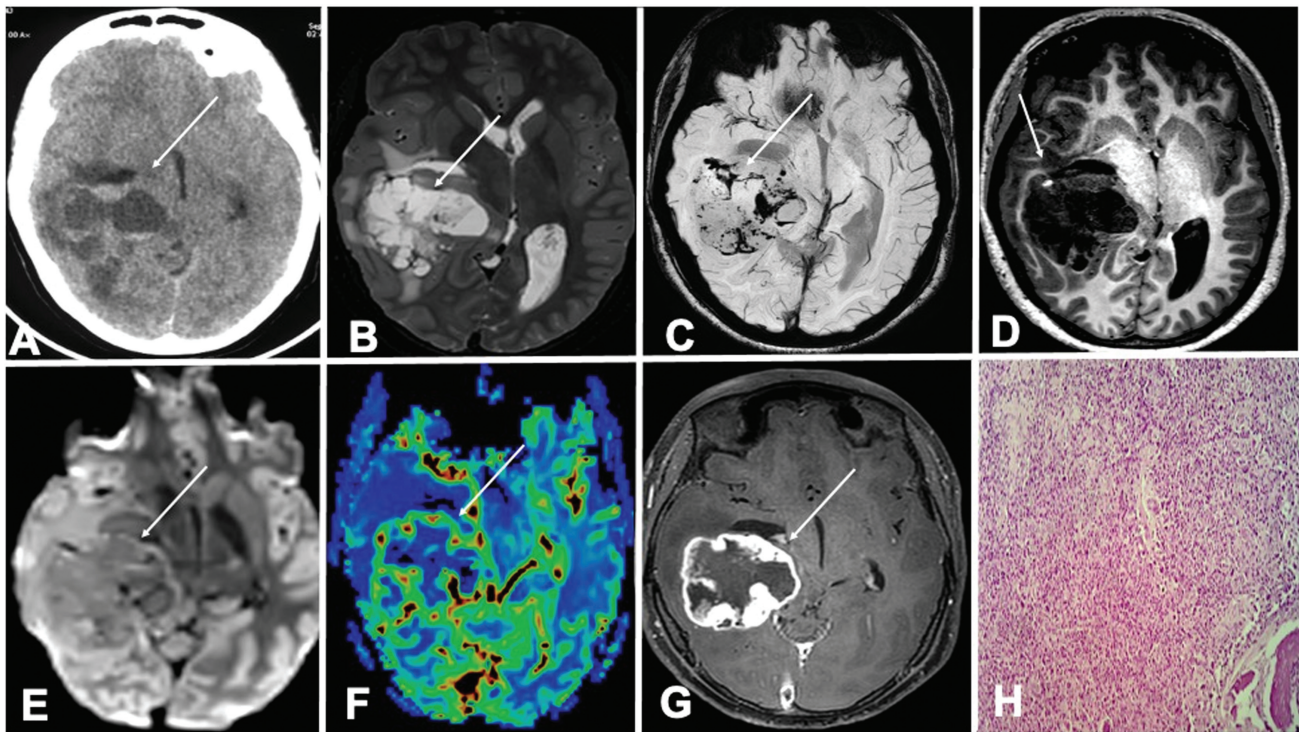


Fig. 2 Magnetic resonance imaging of the brain showing the metastatic lesion within the brain. Axial noncontrast computed tomography head (A) showed a large heterogeneous solid cystic lesion with internal areas of hemorrhage and without calcification in the right posterior temporal lobe (arrow). Axial T2-weighted (B), axial susceptibility-weighted imaging (C), axial T1 (D), and axial diffusion-weighted imaging (E) showed a large solid cystic multiloculated lesion (arrow) with the fluid–fluid level in the right posterior temporal lobe with internal blooming and without restriction. T2* perfusion (F), and axial T1 phase-contrast (G) showed elevated perfusion and irregular shaggy enhancement with nodularity (arrow). Photomicrograph (H) showed malignant mesenchymal tumor exhibiting pleomorphism and hyperchromasia with osteoid matrix production.

(► **Fig. 2H**). The above features were suggestive of metastatic osteosarcoma. The patient was symptomatically better after the procedure, and was further planned for methotrexate, ifosfamide, and etoposide.

Discussion

Osteosarcoma is the most common malignant bone tumor in children and adolescents, distinguished by an osteoid matrix with atypical cells.¹ Osteosarcoma commonly involves the metaphysis of the long tubular bones⁹ and can also occur primarily in skull bones.¹⁰ Different varieties of osteosarcoma in histopathology are osteoblastic, chondroblastic, and fibroblastic, according to predominant features of the cells, but the prognosis and clinical outcome remain the same in these groups.¹¹ The common mechanism for the spread of bone tumors is hematogenous, as the bones are devoid of lymphatics.⁸ Brain metastases are relatively rare in osteosarcoma, with an incidence of 1.8 to 5.6%, and commonly seen in association with lung metastasis, with the postulated mechanism being tumor emboli from the lung migrating to the brain.¹² Mean duration of time interval from the initial diagnosis to brain metastasis in osteosarcoma is 20 months.¹³ We report a case of fibular osteosarcoma in a young female with 2 years of disease-free interval, later presenting with solitary hemorrhagic metachronous cerebral metastases without the involvement of the lung. Metastasis in the brain

is more common with approximately having ten times higher incidence than primary brain tumors.^{14–16} Breast cancer, nonsmall cell lung cancer, and melanoma have their affinity to metastasize to the brain with melanoma as the most common tumor presenting as hemorrhagic brain metastasis.^{14,15} Due to its higher vascularity, these lesions can mimic other tumors like glioblastoma¹⁷ and higher association with intratumoral bleeding.¹⁸ Brain metastasis in sarcoma is relatively rare and approximately only 3% of all brain metastases can develop from sarcomas according to the few studies.^{16,19} Postulated mechanisms are hematogenous dissemination into the brain as the primary cause and contiguous extension from the skull bone to the brain as the secondary cause.²⁰ Similar to other metastatic lesions to the brain, the most common site in osteosarcoma metastasis is the gray-white matter junction in anterior circulation due to an abrupt change in caliber of the perforating vessels supplying the brain parenchyma.²¹ A unique radiological finding in osteosarcoma metastasis brain is large calcifications within the mass lesion and typically described as “bone within the brain” appearance.^{22,23} Our case showed lack of calcification which could be due to the chondroblastic nature of the tumor as evidenced in histopathology. Param et al observed 87 patients and showed that 45% of patients had lung involvement and only 13% of patients had brain metastasis with lung involvement on follow-up. In their study, of those patients who were having brain metastasis,⁴ two had

hemorrhagic components, and one had osteoblastic component and unknown nature in two of the cases on histopathology.⁴ Two of these cases of osteoblastic osteosarcoma were presented with brain metastasis simultaneously with or after lung involvement, for which they suggested periodic screening with disease recurrence.²⁴ Similar case reports were observed where fibroblastic osteosarcoma presented with brain metastasis after 15 months of pneumonectomy for lung metastasis²⁵ and pulmonary, isolated central nervous system relapse can occur in patients with fibroblastic osteosarcoma.^{26,27} Osteosarcoma can present with hemorrhagic cerebellar metastasis, where the patient presented with acute neurologic deterioration²⁸ and multifocal osteosarcomas of the skull presenting with intracranial hemorrhage.²⁹ Isolated cerebral metastasis was also observed in a few cases, and most of the patients presented with raised intracranial hypertension.¹⁷ Sarcoma with brain metastasis is relatively rare and provides a therapeutic challenge to the treating physicians because of resistance to both chemo and radiotherapy.¹⁶ Our case was unique as there was brain metastasis without having lung metastasis and a cardiac defect. No such case report or study was previously available in the literature. We did echocardiography for any septal defect for the right to left shunting and found it to be normal. A possible explanation for our case was that tumor microemboli might escape through the pulmonary circulation to the systemic circulation and get deposited in the brain. One similar case report was available in the literature isolated brain metastasis without lung involvement in a 12 years male child due to patent foramen ovale resulting in the right to left shunt.⁸ Due to the availability of the new chemotherapeutic and radiotherapeutic treatments for soft tissue and bony sarcomas, there was prolonged survival due to systemic disease control, but there was an increased incidence of brain metastases due to less effective intracranial control.^{14,15,19} There was also a higher incidence of brain metastasis in patients with other site metastasis at diagnosis of the tumor and patients with recurrence at 1 year of interval period.¹⁴ The average period from the initial diagnosis of sarcoma to brain metastases is approximately 20 months, according to this study.¹³ Yonemoto et al suggested screening imaging for the brain at a periodic interval in those patients with pulmonary metastasis.³⁰ Contrary to the suggestion by Yonemoto et al, Marina et al stated that routine imaging outcomes are debatable in patients already who had metastasis at the time of diagnosis or recurrence within 12 months of interval period.³¹ Multimodality treatment is often involved in the management of brain metastasis in osteosarcoma patients.¹³ Treatment options for brain metastasis are surgical excision of the lesion with radio and neoadjuvant chemotherapy for the residual disease if any.¹³ Although the long-term follow-up details were not available for solitary brain metastasis, Yonemoto et al in their report showed 6 years of disease-free interval after craniotomy and irradiation for solitary brain metastasis.³⁰

Hemorrhagic brain metastasis without calcification from osteogenic sarcoma, lung involvement, and a septal heart defect, presenting with neurological complaints, is very rare.

It has been postulated that prolonged survival in patients with osteogenic sarcoma due to advances in treatment, results in higher incidence of systemic metastasis.

Conclusion

This case highlights the unique pattern of intracranial metastasis in a case of fibular osteosarcoma that was rarely described in the literature. While following up on osteosarcoma patients, complaints of headache should be investigated for the possibility of brain metastasis.

Declaration of Patient Consent

The authors certify that the appropriate consent forms were taken from the patient. In the consent, she had given the consent for the images and clinical information to be reported to this journal. The patient understands that her name and identity will not be disclosed but anonymity cannot be guaranteed.

Authors' Contributions

MKN and SR designed and wrote the manuscript. AN provided the histopathology And images. SLJ, GT, SR, AN, and MKN critically reviewed and revised the manuscript. Finally, all the authors have read and approved the manuscript. The requirements for authorship have been met, and that each author believes that the manuscript represents honest work.

Disclaimer

The authors certify that they have obtained all appropriate patient consent forms. In the form, the patient(s) has/have given his/her/their consent for his/her/their images and other clinical information to be reported in the journal. The patients understand that their names and initials will not be published and due efforts will be made to conceal their identity, but anonymity cannot be guaranteed.

Source of Funding

None.

Conflict of Interest

None.

Acknowledgement

None.

References

- Rosenberg ZS, Lev S, Schmammann S, Steiner GC, Beltran J, Present D. Osteosarcoma: subtle, rare, and misleading plain film features. *AJR Am J Roentgenol* 1995;165(05):1209–1214
- Luetke A, Meyers PA, Lewis I, Juergens H. Osteosarcoma treatment - where do we stand? A state of the art review. *Cancer Treat Rev* 2014;40(04):523–532
- Casali PG, Bielack S, Abecassis N, et al; ESMO Guidelines Committee, PaedCan and ERN EURACAN. Bone sarcomas: ESMO-PaedCan-EURACAN Clinical Practice Guidelines for diagnosis, treatment and follow-up. *Ann Oncol* 2018;29(Suppl 4):iv79–iv95

- 4 Baram TZ, van Tassel P, Jaffe NA. Brain metastases in osteosarcoma: incidence, clinical and neuroradiological findings and management options. *J Neurooncol* 1988;6(01):47–52
- 5 Bindal RK, Saway RE, Leavens ME, Taylor SH, Guinee VF. Sarcoma metastatic to the brain: results of surgical treatment. *Neurosurgery* 1994;35(02):185–190, discussion 190–191
- 6 Ozarda AT, Legaspi JR, Haynie TP. Detection of a brain metastasis from osteosarcoma with ^{99m}Tc-methylene diphosphonate bone scanning. *Eur J Nucl Med* 1983;8(12):552–554
- 7 Onodera H, Yoshida Y, Sakakibara Y, et al. A case of intracerebral metastasis in osteosarcoma without active pulmonary metastasis. *Br J Neurosurg* 2012;26(01):91–93
- 8 Menassa L, Haddad S, Aoun N, Slaba S, Atallah N. Isolated brain metastases of osteosarcoma in a patient presenting with a patent foramen ovale. *Eur Radiol* 1997;7(03):365–367
- 9 Ottaviani G, Jaffe N. The epidemiology of osteosarcoma. *Cancer Treat Res* 2009;152:3–13
- 10 Ashkan K, Pollock J, D'Arrigo C, Kitchen ND. Intracranial osteosarcomas: report of four cases and review of the literature. *J Neurooncol* 1998;40(01):87–96
- 11 Ozaki T, Flege S, Liljenqvist U, et al. Osteosarcoma of the spine: experience of the Cooperative Osteosarcoma Study Group. *Cancer* 2002;94(04):1069–1077
- 12 Deutsch M, Orlando S, Wollman M. Radiotherapy for metastases to the brain in children. *Radiother Metastases Brain Child* 2002;39(01):60–62
- 13 Shweikeh F, Bukavina L, Saeed K, et al. Brain metastasis in bone and soft tissue cancers: a review of incidence, interventions, and outcomes. *Sarcoma* 2014;2014:475175. Doi: 10.1155/2014/475175
- 14 Kebudi R, Ayan I, Görgün O, Ağaoğlu FY, Vural S, Darendeliler E. Brain metastasis in pediatric extracranial solid tumors: survey and literature review. *J Neurooncol* 2005;71(01):43–48
- 15 Chou YS, Liu CY, Chen WM, et al. Brain, the last fortress of sarcoma: similar dismal outcome but discrepancy of timing of brain metastasis in bone and soft tissue sarcoma. *J Surg Oncol* 2011;104(07):765–770
- 16 Fox BD, Patel A, Suki D, Rao G. Surgical management of metastatic sarcoma to the brain. *J Neurosurg* 2009;110(01):181–186
- 17 Rabah F, Al-Mashaikhi N, Beshlawi I, et al. Brain is not always the last fortress; osteosarcoma with large brain metastasis. *J Pediatr Hematol Oncol* 2013;35(02):e91–e93
- 18 Dwivedi AND, Gupta PK, Gupta K, Garg G. Hemorrhagic brain metastasis from osteogenic sarcoma of iliac bone in young female: unusual site of presentation. *Neurol India* 2011;59(04):639–640
- 19 Salvati M, D'Elia A, Frati A, Santoro A. Sarcoma metastatic to the brain: a series of 35 cases and considerations from 27 years of experience. *J Neurooncol* 2010;98(03):373–377
- 20 Postovsky S, Ash S, Ramu IN, et al. Central nervous system involvement in children with sarcoma. *Oncology* 2003;65(02):118–124
- 21 Singh SK, Leeds NE, Ginsberg LE. MR imaging of leptomeningeal metastases: comparison of three sequences. *AJNR Am J Neuroradiol* 2002;23(05):817–821
- 22 Kokkali S, Andriotis E, Katsarou E, et al. Cerebral metastasis from osteosarcoma: “Bone” in the brain. *Radiol Case Rep* 2020;15(06):780–783
- 23 De Pablo-Fernández E, Gómez-Herrera JJ, Sierra-Hidalgo F, Sanchez-Ferro A. Calcified brain metastases from osteosarcoma. *Can J Neurol Sci* 2013;40(02):247–248
- 24 Mateos González ME, López-Laso E, Garrido Colino C, Torres Valdivieso MJ, López Pérez J, Simón De Las Heras R. [Osteosarcoma and brain metastasis]. *An Esp Pediatr* 2002;56(05):462–465
- 25 Doval DC, Chacko M, Sinha R, et al. A rare case of brain metastasis in a patient with osteosarcoma. *South Asian J Cancer* 2017;6(01):36–37
- 26 Wexler LH, DeLaney TF, Saris S, Horowitz ME. Long-term survival after central nervous system relapse in a patient with osteosarcoma. *Cancer* 1993;72(04):1203–1208
- 27 Nieto-Coronel MT, López-Vásquez AD, Marroquín-Flores D, Ruiz-Cruz S, Martínez-Tláhuel JL, De la Garza-Salazar J. Central nervous system metastasis from osteosarcoma: case report and literature review. *Rep Pract Oncol Radiother* 2018;23(04):266–269
- 28 Niazi TN, Forester C, Afify Z, Riva-Cambrin J. Osteosarcoma presenting as hemorrhagic cerebellar metastasis. *Childs Nerv Syst* 2009;25(12):1643–1647
- 29 Sato H, Hayashi N, Yamamoto H, et al. Synchronous multifocal osteosarcoma involving the skull presenting with intracranial hemorrhage - case report. *Neurol Med Chir (Tokyo)* 2010;50(05):407–409
- 30 Yonemoto T, Tatezaki S, Ishii T, Osato K, Takenouchi T. Long-term survival after surgical removal of solitary brain metastasis from osteosarcoma. *Int J Clin Oncol* 2003;8(05):340–342
- 31 Marina NM, Pratt CB, Shema SJ, Brooks T, Rao B, Meyer WH. Brain metastases in osteosarcoma. Report of a long-term survivor and review of the St. Jude Children's Research Hospital experience. *Cancer* 1993;71(11):3656–3660