

# Bilateral CMV Retinitis in a Patient with Relapsed Non-Hodgkin Lymphoma on Oral Metronomic Chemotherapy: Case Report and Review of Literature

Fen Saj<sup>1</sup> Amit Kumar Deb<sup>2</sup> Subhashini Kaliaperumal<sup>2</sup> Smita Kayal<sup>1</sup> Biswajit Dubashi<sup>1</sup>   
Rahul Dhodapkar<sup>3</sup> Prasanth Ganesan<sup>1</sup> 

<sup>1</sup> Department of Medical Oncology, Jawaharlal Institute of Postgraduate Medical Education and Research (JIPMER), Puducherry, India

<sup>2</sup> Department of Ophthalmology, Jawaharlal Institute of Postgraduate Medical Education and Research (JIPMER), Puducherry, India

<sup>3</sup> Department of Microbiology, Jawaharlal Institute of Postgraduate Medical Education and Research (JIPMER), Puducherry, India

Address for correspondence Prasanth Ganesan, MD, DM, Department of Medical Oncology, 3<sup>rd</sup> Floor, SSB, JIPMER, Dhanvantari Nagar, Puducherry 605006, India (e-mail: p.ganesan@jipmer.edu.in).

Ind J Med Paediatr Oncol

## Abstract

### Keywords

- ▶ case report
- ▶ lymphoma
- ▶ oral metronomic chemotherapy
- ▶ cytomegalovirus
- ▶ retinitis

Cytomegalovirus (CMV) retinitis is one of the common complications in profoundly immunosuppressed patients such as those with acquired immune deficiency syndrome. It has been rarely reported in patients with lymphoma on aggressive chemotherapy. We encountered a patient with bilateral CMV retinitis who developed this vision-threatening complication while on low-dose palliative metronomic chemotherapy with oral drugs (cyclophosphamide, procarbazine, etoposide, and prednisolone). Though the infection resolved with treatment, there was residual vision loss. This case is presented to sensitize clinicians to the possibility of unusual infections in patients on long-term oral chemotherapies.

## Introduction

Oral metronomic chemotherapy (OMCT) is often used in patients with relapsed lymphomas. The toxicities of OMCT are generally lower than those of intravenous chemotherapy, making it a preferable option in patients with advanced disease or poor general condition. However, prolonged use of OMCT can lead to immunosuppression and result in unusual infections.<sup>1</sup> Here we describe a rare case of bilateral cytomegalovirus (CMV) retinitis in a patient with relapsed Non-Hodgkin Lymphoma on OMCT.

## Case Report

In 2014, a 52-year-old gentleman with no comorbidities with grade 1, stage IV follicular lymphoma achieved complete response after six cycles of rituximab, cyclophosphamide, doxorubicin, vincristine, prednisolone (R-CHOP) chemotherapy. He relapsed in 2017, and lymph node biopsy was suggestive of diffuse large B cell lymphoma. He was treated with rituximab, cyclophosphamide, epirubicin, vincristine, prednisolone (R-CEOP) as he was unwilling for high dose chemotherapy or stem cell transplantation. After five cycles

DOI <https://doi.org/10.1055/s-0042-1742614>.  
ISSN 0971-5851.

© 2022. Indian Society of Medical and Paediatric Oncology. All rights reserved.

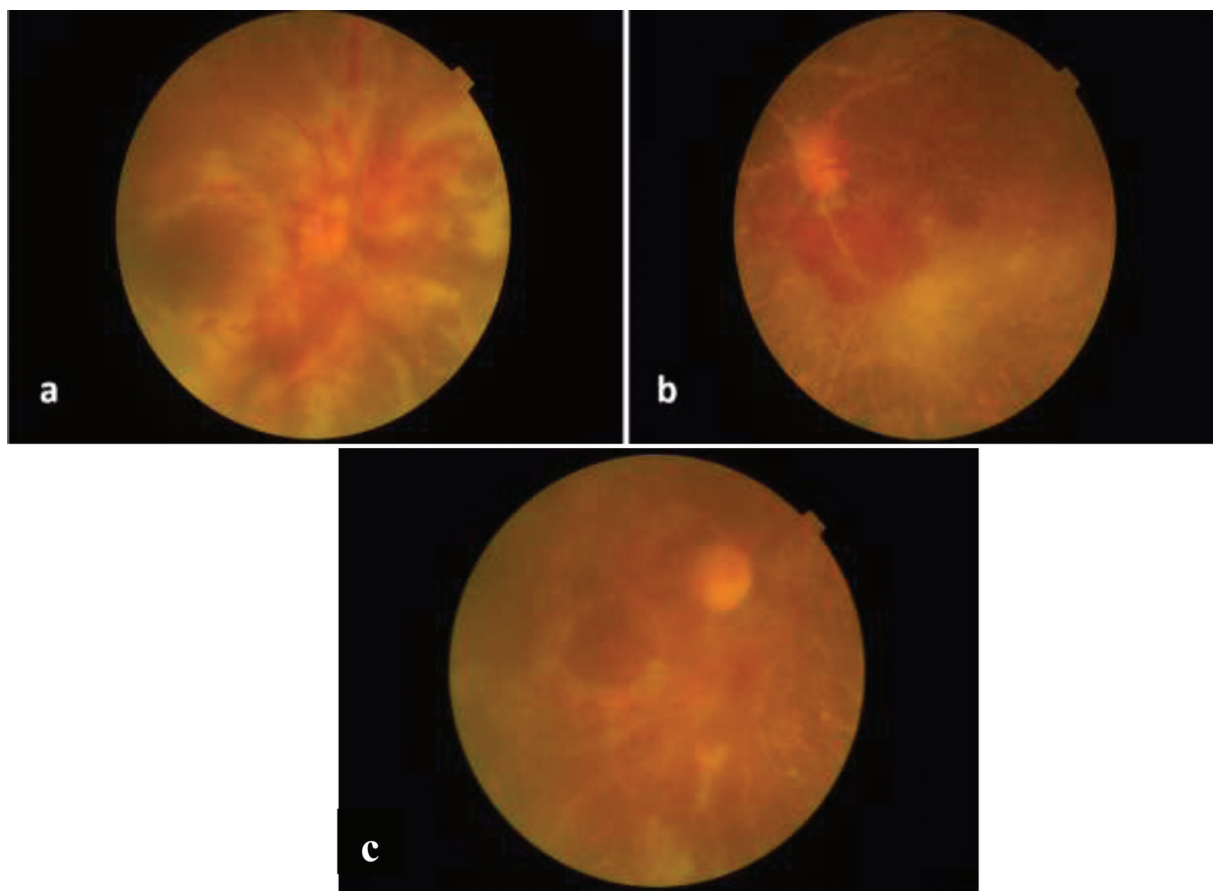
This is an open access article published by Thieme under the terms of the Creative Commons Attribution-NonDerivative-NonCommercial-License, permitting copying and reproduction so long as the original work is given appropriate credit. Contents may not be used for commercial purposes, or adapted, remixed, transformed or built upon. (<https://creativecommons.org/licenses/by-nc-nd/4.0/>)

Thieme Medical and Scientific Publishers Pvt. Ltd., A-12, 2nd Floor, Sector 2, Noida-201301 UP, India

of R-CEOP, he developed a persistent headache. The MRI brain was within normal limits, but the cerebrospinal fluid analysis showed lymphomatous involvement. He was unwilling for any intensive treatment and was started on OMCT with the PEP-C regimen comprising of prednisolone 20 mg once daily for 14 days, etoposide 50 mg once daily for 28 days, procarbazine 50 mg once daily for 28 days, cyclophosphamide 50 mg once daily for 28 days, and triple intrathecal therapy comprising of inj. methotrexate 12 mg, inj. cytarabine 30 mg, and inj. hydrocortisone 15 mg.<sup>2</sup> His symptoms improved significantly after two to three cycles of OMCT. CSF cytology became negative for malignant cells after four cycles of OMCT, and the contrast-enhanced CT scan of the chest, abdomen, pelvis showed no evidence of systemic disease.

In 2019, after 13 courses of PEP-C regimen, he presented with acute onset, painless diminution of vision in both the eyes—right eye (RE) more than the left eye (LE). Visual acuity was hand movements in RE and 6/18 in LE. Fundus examination in both eyes revealed scattered whitish lesions on the retina suggestive of retinitis, along with superficial retinal hemorrhages and perivascular exudates involving the major retinal vessels. The lesions involved the macular center in the RE while the same was spared in the LE (► Fig. 1). There

was no associated vitritis. The differential diagnoses considered were intraocular lymphoma and CMV retinitis. The vitreal aspirate was positive for CMV DNA (deoxyribonucleic acid) PCR (polymerase chain reaction) and negative for malignant cells on cytology. The peripheral blood CMV DNA PCR was positive; however, there were no symptoms of disseminated CMV infection. He had no chest or gastrointestinal symptoms; chest X-ray and LFTs were normal. Thus, there was no evidence of systemic CMV infection. HIV serology was negative. He was managed with intravitreal ganciclovir (2 mg/0.1 mL, weekly once, six doses for each eye) and intravenous ganciclovir (10 mg/kg in two divided doses daily for 1 month). This was followed by oral valganciclovir 900 mg twice daily for 21 days and once daily for 2 months. Gradually, the retinal lesions resolved and manifested healing. CMV DNA PCR of the blood or vitreal aspirate was not repeated, and the disappearance of the retinal vascular sheathing was taken as a marker of clinical improvement. The visual acuity in the RE improved to counting fingers while the LE vision improved to 6/9. OMCT was discontinued as the relapsed lymphoma had shown complete clinical and radiologic response. The patient is currently on follow-up and is alive and well 2 years after the event.



**Fig. 1** Fundusoscopic images of both eyes at presentation. Fundus images showing (a) right eye: white retinitis lesions with retinal hemorrhages and perivascular sheathing with involvement of the optic disk and the macula; (b) Left eye: white retinitis lesions with retinal hemorrhages and perivascular sheathing with involvement of infero-temporal retinal quadrant and sparing of the center of the macula; (c) image of the right eye after 2 months showing improvement in retinal hemorrhages and perivascular sheathing.

**Table 1** Case reports of cytomegalovirus retinitis in patients treated for lymphoma

Sl no	Author (Ref)	Lymphoma subtype	Chemotherapy	Diagnosis	Treatment given for CMV retinitis	Visual outcome
1.	Smith <sup>15</sup>	HL	MP	Inclusion body bearing cells (post-mortem)	NR	Patient died
2.	Nasir and Jaffe <sup>16</sup>	HL	MOPP-ABVD	Vitreous biopsy and CMV DNA PCR	IV gan f/b IV foscarnet	Improved
3.	Toy and Knowlden <sup>17</sup>	HL (R)	Chl-VPP	Inclusion body bearing cells (post-mortem)	Post mortem diagnosis	Patient died
4.	Tudesq et al <sup>18</sup>	HL (R)	BV	Vitreous humor aspirate and CMV DNA PCR	IVtr and IV Gan f/b PO Valgan	NR
5.	Tyagi et al <sup>19</sup>	B-NHL	R-CHOP	Vitreous biopsy and CMV DNA PCR	IVtr and IV Gan f/b PO Valgan	Improved left eye: Total visual loss
6.	Kang <sup>20</sup>	DLBCL	R-CHOP	Vitreous aspirate and CMV DNA PCR	IVtr and IV Gan	Improved
7.	Kawai et al <sup>21</sup>	AITL	CHOP	Peripheral blood CMV DNA PCR	IVtr and IV Gan	Improved
8.	Chawla et al <sup>22</sup>	NHL	CHOP	Vitreous biopsy and CMV DNA PCR	Observation	Stable disease
9.	Akpek et al <sup>23</sup>	NHL	NR	Diagnostic vitrectomy and CMV DNA PCR	IV gan	Bilateral visual loss
10.	Vote et al <sup>24</sup>	PSPL	Splenectomy, CHOP	Vitreous aspirate and CMV DNA PCR	IV gan f/b IV foscarnet	Stable
11.	Derzko et al <sup>25</sup>	DLBCL (R)	Alemtuzumab, Fludarabine	CMV DNA PCR of vitreal fluid	IV gan and foscarnet	Did not improve
12.	Reddy et al <sup>26</sup>	NHL	Various chemotherapy	CMV DNA PCR of vitreal fluid	IVtr, IV Gan and PO Valgan	Improved
13.	Current patient	DLBCL	PEP-C oral	CMV DNA PCR of vitreal aspirate	IVtr, IV Gan f/b PO Valgan	Improved

Abbreviations: (R), relapsed disease; ABVD, doxorubicin, bleomycin, vinblastine, dacarbazine; AITL, angioimmunoblastic T-cell lymphoma; BV, brentuximab vedotin; CHOP, cyclophosphamide, doxorubicin, vincristine, prednisolone; CVP, cyclophosphamide, vincristine, prednisolone; CVPP, chlorambucil, vinblastine, procarbazine, prednisolone; DLBCL, diffuse large B cell lymphoma; DNA, deoxyribonucleic acid; FL, follicular lymphoma; Gan, ganciclovir; HL, Hodgkin lymphoma; IV, intravenous; IVtr, intravitreal; MOPP/ABVD, mechlorethamine, vincristine, procarbazine, prednisolone, doxorubicin, bleomycin, vinblastine, dacarbazine; MP, mechlorethamine, prednisolone; NHL, non-Hodgkin lymphoma; NR, not reported; PCR, polymerase chain reaction; PO, peroral; PSPL, primary splenic plasmacytoid lymphoma; Valgan, valganciclovir; PEP-C, oral procarbazine, etoposide, prednisolone, and cydophosphamide; CMV, Cytomegalovirus; DNA, Deoxyribonucleic acid.

## Discussion

Our patient had relapsed lymphoma and was on chronic low dose chemotherapy with potential for immune suppression. There were two primary differential diagnoses. One was lymphomatous involvement of the eye, considering the earlier history of meningeal involvement. The second was infectious retinitis, e.g., CMV, toxoplasmosis, candida, pneumocystis, varicella-zoster, and herpes simplex infections.<sup>3</sup> Intraocular lymphoma usually presents as chronic posterior uveitis involving the vitreous (increased haze and cellularity). Additionally, retinitis (perivascular yellowish-white retinal infiltrates and intraretinal hemorrhages) and retinal vasculitis (sheathing of blood vessels) may ensue.<sup>4</sup> CMV retinitis can closely mimic the retinal presentation of intraocular lymphoma.<sup>5</sup> CMV retinitis is seen in 5 to 20% of patients undergoing solid organ transplantation and in 15

to 30% of those undergoing allogeneic hematopoietic stem cell transplantation.<sup>6,7</sup> It presents as focal, perivascular retinal whitening with or without intraretinal hemorrhages and progresses in centrifugal or “brushfire” pattern. It can progress to full-thickness retinal necrosis and retinal detachment.<sup>6</sup> In this patient, the diagnosis was established by detecting CMV DNA PCR of the vitreal aspirate.

CMV serology cannot be used as the sole diagnostic investigation as it can be positive in 80 to 90% of the general population in India.<sup>8</sup> The gold standard of diagnosis is the isolation of the virus in culture—however, CMV culture is challenging. It takes a long time and is falsely negative in 50% of cases.<sup>9,10</sup> On the contrary, DNA amplification techniques (PCR) from blood or vitreal aspirate provide a timely diagnosis with high sensitivity and specificity.<sup>11,12</sup> CMV retinitis is vision-threatening, and treatment has to be instituted as soon as the diagnosis is established. Intravitreal treatment is

vital in vision-threatening disease (central lesions <1,500 µm from the fovea or closer to the optic nerve head). However, systemic anti-CMV treatment cannot be avoided. One-third of the patients treated with intravitreal therapy alone develop extraocular CMV disease and contralateral retinitis.<sup>13</sup> Hence, a combination of intravitreal plus systemic therapy is preferred as was used in our patient. When the disease is not immediately vision-threatening, systemic therapy can be used (IV ganciclovir, IV foscarnet, IV cidofovir, and oral valganciclovir) without intravitreal treatment. Patients are to be monitored with indirect ophthalmoscopy weekly/once in 2 weeks while on induction therapy and monthly till the completion of anti-CMV treatment.<sup>14</sup>

Several cases of CMV retinitis in patients with lymphoma have been described (–Table 1). Most cases developed in patients on aggressive chemotherapy regimens, which are more likely to produce myelosuppression and immune suppression. Unfortunately, limited data are available regarding risk of CMV relapse while salvaging further relapses. One of the options is to continue chemotherapy with close monitoring of CMV DNA, as is done in the context of an allogeneic transplant. The other option is to avoid immunosuppressive regimens which are heavy on steroids. Our report is the first one describing CMV retinitis during OMCT. The strength of our study is that it highlights that CMV infection is a rare but serious complication of a seemingly less intensive treatment like oral metronomic chemotherapy. The weakness is that we do not have information on the immune status of the patient, like the CD4 counts or immune globulin levels.

## Conclusion

Despite low doses, long-term use of cyclophosphamide and prednisolone possibly induces a chronic immunodeficiency state making the patients susceptible to rare infections. This case is presented to alert clinicians about unusual but severe infections in patients on OMCT.

### Declaration of Patient Consent

The authors certify that they have obtained all appropriate patient consent forms.

### Funding

None.

### Conflict of Interest

None declared.

### Acknowledgment

None.

## References

- Santos KD, Lien K, Georgsdottir S, Sivanathan L, Emmenegger U. Adverse side effects associated with the use of low-dose metronomic chemotherapy. In: Bocci G, Francia G, eds. *Metronomic Chemotherapy: Pharmacology and Clinical Applications*. Berlin, Heidelberg: Springer; 2014:263–279
- Coleman M, Martin P, Ruan J, et al. Low-dose metronomic, multidrug therapy with the PEP-C oral combination chemotherapy regimen for mantle cell lymphoma. *Leuk Lymphoma* 2008;49(03):447–450
- Guembel HO, Ohrloff C. Opportunistic infections of the eye in immunocompromised patients. *Ophthalmologica* 1997;211(Suppl 1):53–61
- Brown SM, Jampol LM, Cantrill HL. Intraocular lymphoma presenting as retinal vasculitis. *Surv Ophthalmol* 1994;39(02):133–140
- Tang L-J, Gu C-L, Zhang P. Intraocular lymphoma. *Int J Ophthalmol* 2017;10(08):1301–1307
- Dhillon B. The management of cytomegalovirus retinitis in AIDS. *Br J Ophthalmol* 1994;78(01):66–69
- Azevedo LS, Pierrotti LC, Abdala E, et al. Cytomegalovirus infection in transplant recipients. *Clinics (São Paulo)* 2015;70(07):515–523
- Chakravarti A, Kashyap B, Matlani M. Cytomegalovirus infection: an Indian perspective. *Indian J Med Microbiol* 2009;27(01):3–11
- Shibata D, Martin WJ, Appleman MD, Causey DM, Leedom JM, Arnheim N. Detection of cytomegalovirus DNA in peripheral blood of patients infected with human immunodeficiency virus. *J Infect Dis* 1988;158(06):1185–1192
- Salmon D, Lacassin F, Harzic M, et al. Predictive value of cytomegalovirus viraemia for the occurrence of CMV organ involvement in AIDS. *J Med Virol* 1990;32(03):160–163
- Fox GM, Crouse CA, Chuang EL, et al. Detection of herpesvirus DNA in vitreous and aqueous specimens by the polymerase chain reaction. *Arch Ophthalmol* 1991;109(02):266–271
- Mitchell SM, Fox JD, Tedder RS, Gazzard BG, Lightman S. Vitreous fluid sampling and viral genome detection for the diagnosis of viral retinitis in patients with AIDS. *J Med Virol* 1994;43(04):336–340
- Jabs DA, Ahuja A, Van Natta M, Dunn JP, Yeh S. Studies of the Ocular Complications of AIDS Research Group. Comparison of treatment regimens for cytomegalovirus retinitis in patients with AIDS in the era of highly active antiretroviral therapy. *Ophthalmology* 2013;120(06):1262–1270
- Kaplan JE, Benson C, Holmes KK, Brooks JT, Pau A, Masur H, et al. Guidelines for prevention and treatment of opportunistic infections in HIV-infected adults and adolescents: recommendations from CDC, the National Institutes of Health, and the HIV Medicine Association of the Infectious Diseases Society of America. *MMWR Recomm Rep Morb Mortal Wkly Rep Recomm Rep* 2009;58:1–207; quiz CE1–4
- Smith ME. Retinal involvement in adult cytomegalic inclusion disease. *Arch Ophthalmol* 1964;72(72):44–49
- Nasir MA, Jaffe GJ. Cytomegalovirus retinitis associated with Hodgkin's disease. *Retina* 1996;16(04):324–327
- Toy JL, Knowlden RP. Cytomegalovirus retinitis misdiagnosed as Hodgkin's lymphoma deposits. *BMJ* 1978;2(6149):1398–1399
- Tudesq J-J, Vincent L, Lebrun J, et al. Cytomegalovirus infection with retinitis after brentuximab vedotin treatment for CD30<sup>+</sup> lymphoma. *Open Forum Infect Dis* 2017;4(02):ofx091
- Tyagi M, Ambiya V, Mathai A, Narayanan R. Atypical cytomegalovirus retinitis in non-Hodgkin's lymphoma. *BMJ Case Rep*. 2015. Accessed June 17, 2021 at: <https://www.ncbi.nlm.nih.gov/pmc/articles/PMC4533632/>
- Kang HM. Cytomegalovirus retinitis in patients with diffuse large B-cell lymphoma. *J. Retin* 2017;2:97–100
- Kawai Y, Kawai R, Nakayama T, et al. Successful treatment of cytomegalovirus retinitis in a patient with malignant lymphoma: a case report and review of the literature. *Int J Hematol* 1999;69(04):256–259
- Chawla R, Venkatesh P, Garg SP, Mandal S, Tewari HK. Cytomegalovirus retinitis in a patient with non-Hodgkins lymphoma: a diagnostic dilemma. *Eur J Ophthalmol* 2005;15(01):153–157

- 23 Akpek EK, Kent C, Jakobiec F, Caliendo AM, Foster CS. Bilateral acute retinal necrosis caused by cytomegalovirus in an immunocompromised patient. *Am J Ophthalmol* 1999;127(01):93-95
- 24 Vote B, Russell M, Polkinghorne P. Recurrent cytomegalovirus retinitis in a patient with a normal lymphocyte count who had undergone splenectomy for lymphoma. *Retina* 2005;25(02):220-221
- 25 Derzko-Dzulynsky LA, Berger AR, Berinstein NL. Cytomegalovirus retinitis and low-grade non-Hodgkin's lymphoma: case report and review of the literature. *Am J Hematol* 1998;57(03):228-232
- 26 Reddy S, Tyagi M, Behera S, et al. Cytomegalovirus retinitis in patients of non-Hodgkin's lymphoma: clinical presentations and outcomes. *J Ophthalmic Inflamm Infect* 2021;11(01):26