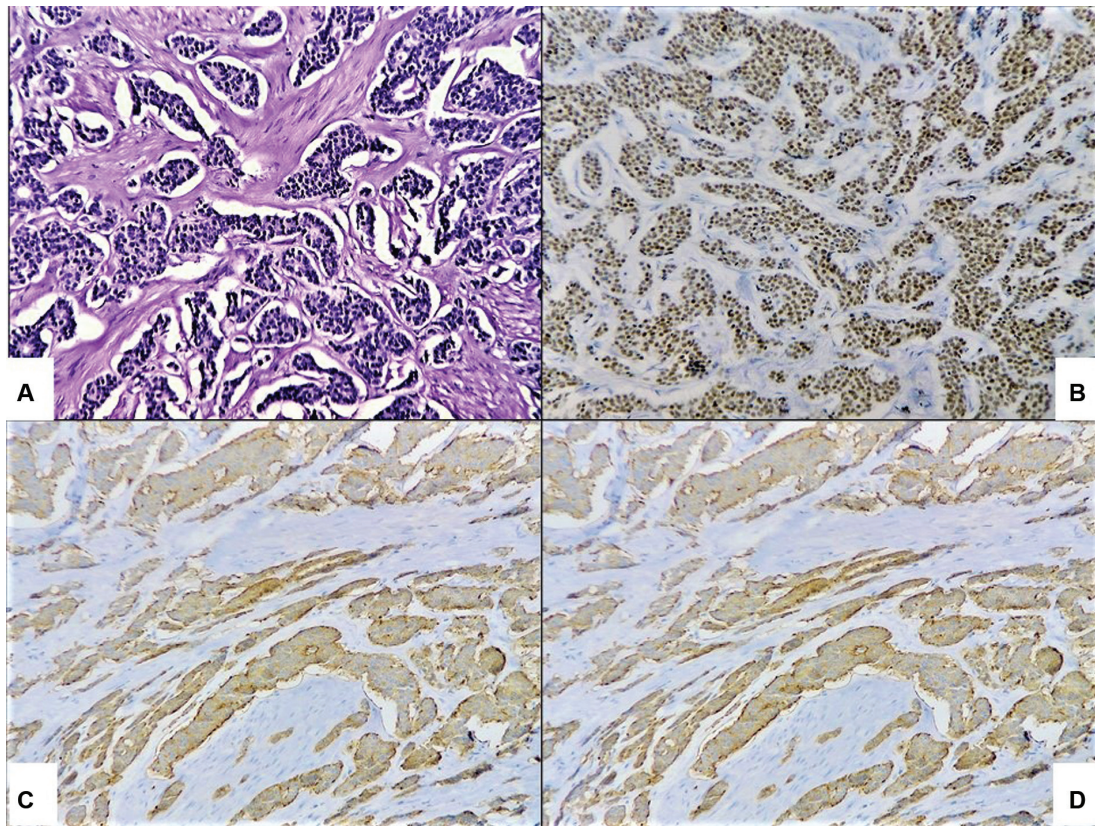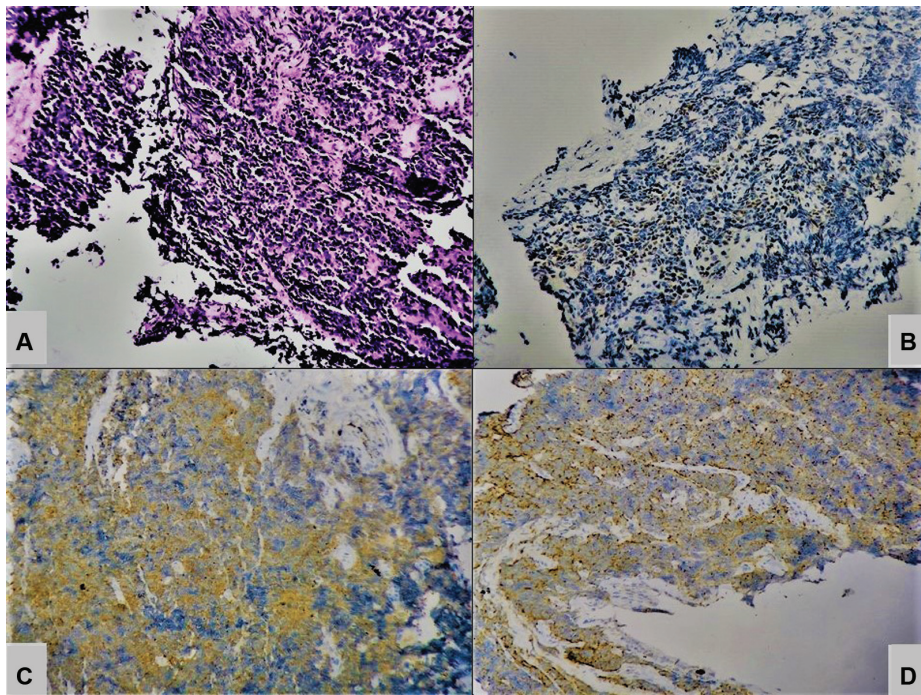


Supp. Fig. 1 Photomicrograph of well-differentiated neuroendocrine tumor (WD-NET). (A) Histopathology. (B) Insulinoma-associated protein 1 (INSM1) nuclear staining. (C) Synaptophysin (SYN) cytoplasmic staining. (D) Chromogranin A (CgA) cytoplasmic staining (diaminobenzidine [DAB], 20 \times).



Supp. Fig. 2 Photomicrograph of poorly differentiated neuroendocrine carcinoma (PD-NEC). (A) Histopathology. (B) Insulinoma-associated protein 1 (INSM1) nuclear staining. (C) Synaptophysin (SYN) cytoplasmic staining. (D) Chromogranin A (CgA) cytoplasmic staining (diaminobenzidine [DAB], 20 \times).